

Consensus for Nonmelanoma Skin Cancer Treatment, Part II: Squamous Cell Carcinoma, Including a Cost Analysis of Treatment Methods

ARIELLE N. B. KAUVAR, MD,^{*†} CHRISTOPHER J. ARPEY, MD,[‡] GEORGE HRUZA, MD,^{§||} SUZANNE M. OLBRICHT, MD,[¶] AND RICHARD BENNETT, MD^{**}

BACKGROUND Cutaneous squamous cell carcinoma (cSCC) is the second most common cancer in the United States. Cutaneous squamous cell carcinoma has an estimated incidence of more than 700,000 new cases per year and a 5% risk of metastasis.

OBJECTIVE To provide clinicians with guidelines for the management of cSCC based on evidence from a comprehensive literature review and consensus among the authors.

MATERIALS AND METHODS The authors conducted an extensive review of the medical literature on treatment methods for cSCC, taking into consideration cure rates, recurrence and metastatic rates, aesthetic and functional outcomes, and cost effectiveness of the procedures.

RESULTS Surgical treatments provide the best outcomes for cSCC. Mohs micrographic surgery is a cost-effective procedure that affords the highest cure rate, maximal tissue preservation, and superior cosmetic outcomes. Nonsurgical methods may be used as a primary treatment for low-risk squamous cell carcinomas, but the cure rates are lower.

CONCLUSION The cure rate remains the most important consideration in choosing the treatment method, but additional factors, such as the patient's general medical condition, psychosocial circumstances, the location of the tumor and cost effectiveness of the therapy should be considered. Mohs micrographic surgery remains the preferred treatment for high-risk tumors and tumors located in cosmetically sensitive areas.

The authors have indicated no significant interest with commercial supporters.

Cutaneous squamous cell carcinoma (cSCC)—both Bowen and non-Bowen disease type—is a very common skin cancer, especially in light-skin persons. In the United States, cSCC accounts for 20% of skin malignancies with an estimated annual incidence of 700,000.^{1–4} Cutaneous squamous cell is not only the second most common skin cancer type (the first being basal cell carcinoma [BCC]), it is also the second most common malignancy type.^{1–4}

Although many cSCCs are small low-risk cancers that are easily treated in physicians' offices by minor surgical procedures, some cSCCs can become problematic. When cSCCs continue to grow, they can cause significant local tissue destruction and invade blood vessels, nerves, muscles, bones, and vital organs such as the eye. Thus, significant morbidity and cosmetic deformity can occur. Furthermore, metastases and death can ensue if the progression of cSCC is not halted.

^{*}New York University School of Medicine, New York, New York; [†]New York Laser & Skin Care, New York, New York; [‡]Mayo Clinic, Rochester, Minnesota; [§]St. Louis University, St Louis, Missouri; ^{||}Laser & Dermatologic Surgery Center, Chesterfield, Missouri; [¶]Lahey Clinic; Associate Professor, Harvard Medical School, Boston, Massachusetts; [#]David Geffen School of Medicine, University of California Los Angeles, Los Angeles, California; ^{**}Keck School of Medicine, University of Southern California, Los Angeles, California

© 2015 by the American Society for Dermatologic Surgery, Inc. Published by Wolters Kluwer Health, Inc. All rights reserved.
ISSN: 1076-0512 • *Dermatol Surg* 2015;41:1214–1240 • DOI: 10.1097/DSS.0000000000000478

The primary goal of cSCC treatment is complete tumor eradication with maximal preservation of function and excellent cosmesis. The purpose of this consensus article is to assist the physician in choosing the optimal treatment approach for cSCC, while taking into consideration patient and tumor risk factors and also efficacy and cost.

Epidemiology

Most cSCCs occur on the head, neck, and extremities— anatomic areas that receive the maximum amount of sunlight.⁵ Cutaneous squamous cell carcinoma is most common in light-skin persons of western European descent.^{6,7} Cutaneous squamous cell carcinoma occurs more often in men than in women (with a man to woman ratio of 3:1), and its incidence increases with age in both genders.^{6,7} Comparatively, cSCC is rare in Blacks and Asians, but it is the most common skin cancer type in these populations.^{6,8} Cutaneous squamous cell carcinoma is more prevalent at low latitudes where the ultraviolet (UV) index is high.^{3,9–11} In these low latitudes, the relative risk of cSCC is 3 times higher for people born there than that in people who move to these same locations. Individuals with outdoor occupations have a 5 times higher risk for cSCC development than that for those with indoor occupations, and those who frequent tanning salons also have a high risk of cSCC.¹²

The cSCC incidence has been increasing for several decades.^{1,13} Population-based incidence studies during the 1980s and 1990s indicate that the cSCC incidence rate more than doubled over a period of 14 years in New Hampshire¹⁴ and doubled over a period of 21 years in New Mexico.¹⁵ Based on billed treatments, the incidence of cSCC rose in the United States over the last several decades by estimated rates of 4% to 23% per year.^{13,16}

Factors contributing to the increased risk of cSCC may include early detection, population shifts to sunbelt states, increase in outdoor activities, increased tanning bed use, depletion of the ozone layer, an increase in immunosuppressive drug therapy, and a longer life-span than that in previous generations.^{1,17}

The exact mortality incidence from cSCC in the United States is unknown because all cSCCs are not tracked in

the Surveillance, Epidemiology, and End Results (SEER) Program of the National Cancer Institute. However, there have been a few isolated estimates.¹⁸ A 10-year retrospective cohort study in a Boston academic hospital showed that patients with cSCC had a 3.7% incidence of metastasis and 2.1% risk of disease-specific death.¹⁹ Aggressive or high-risk cSCCs are estimated to result in approximately 8,000 cases of nodal metastases and 3,000 deaths each year.^{20,21} Cutaneous squamous cell carcinoma has a higher mortality rate in Blacks than that in whites, possibly because of delayed diagnosis and/or that these tumors occur commonly in sun protected skin and in sites of previous trauma or scarring.^{22,23}

Despite the increasing incidence of cSCC, population-based and cohort studies indicate that cSCC mortality has been decreasing for decades, presumably because of early detection and effective treatment of cSCCs before these tumors have metastasized.^{10,24–26} For instance, the age-adjusted mortality rate for confirmed cases of nongenital cSCC in Rhode Island went from 0.26 per 100,000 between 1979 and 1987 to 0.21 per 100,000 between 1988 and 2000.^{27,28}

Pathogenesis and Etiology

Ultraviolet Radiation Exposure

The principal risk factor for the development of cSCC is the cumulative lifetime exposure to UV radiation. UV-B radiation (290–320 nm) is the primary cause, but UV-A radiation (320–400 nm) also contributes to the risk.²⁹

Ultraviolet radiation induces “UV signature” mutations in DNA, the formation of thymidine dimers in the p53 tumor suppressor gene; this damaged gene impairs cell cycle control and results in the clonal expansion of keratinocytes. The UV-type p53 mutation is also found in actinic keratosis (AK), the precursor lesion of cSCC. Ultraviolet radiation also induces dose-dependent suppression of cellular immunity and interferes with immune surveillance of skin cancer.^{12,30–32} Ultraviolet light treatments for inflammatory diseases such as psoriasis increase the

risk for cSCC; UV-A light with oral psoralen is particularly photocarcinogenic.^{33,34}

Skin Phototype

Fitzpatrick skin typing subjectively categorizes skin sensitivity to UV light and is a good predictor of relative risk for cSCC. Those patients with light skin, blond or red hair, and blue or hazel eyes are 2 to 5 times more likely to develop cSCC than those with dark skin and brown eyes.³⁵ Patients with vitiligo and oculocutaneous albinism are at very high risk for the development of cSCC.^{36,37}

History of Previous Cutaneous Squamous Cell Carcinoma

There is a 30% to 50% increased risk of another primary cSCC within 5 years after treatment of the first cSCC.^{38–40}

Chemical Exposures

Arsenic exposure induces cSCC, especially Bowen disease (BD) carcinoma, BCC, AKs, and internal cancers.⁴¹ Polycyclic aromatic hydrocarbons such as tar, pitch, and soot also increase the risk of cSCC. Cutaneous squamous cell carcinoma of the scrotum is common in workers using pitch or cutting oils and in chimney sweeps from soot exposure.⁴²

Chronic Scars

Cutaneous squamous cell carcinoma may arise in sites of chronic inflammation, osteomyelitis, sinus tracts, ulcers, and scars.^{43,44} Marjolin ulcer refers to a cSCC that originates in a long-standing cutaneous scar, usually presenting 30 to 40 years after the injury.

Chronic Skin Disorders

Chronic dermatoses associated with an increased risk for the development of cSCC include prokeratosis, discoid lupus, lupus vulgaris, lichen sclerosus et atrophicus, lymphogranuloma venereum, granuloma inguinale, lichen planus, acne conglobata, hidradenitis suppurativa, dystrophic epidermolysis bullosa (EB), and erythema ab igne.³

Viruses

Human papillomavirus (HPV) infection can be linked with the development of cSCC. Human papillomavirus Types 6, 11, 16, and 18 are commonly found in cSCC of the genitalia and Type 16 is associated specifically with periungual cSCC.⁴⁵ In epidermodysplasia verruciformis, an autosomal recessive disorder with an abnormal susceptibility to β -HPV (HPV-5), there is an increased risk of cSCC.⁴⁶ A systematic review of the literature⁴⁷ showed that cSCCs are more likely to carry HPV than normal-appearing skin in all patients, and cSCCs in immunosuppressed patients have an increased prevalence of HPV compared with those in immunocompetent patients. However, the role of HPV in cSCC, remains poorly defined.⁴⁷ One issue regarding the testing of HPV with cSCC is that cSCC is either BD type carcinoma or non-Bowen disease type carcinoma. Because pathologists and researchers frequently lump these 2 entities together and because oncogenic HPV has been found with great frequency in both periungual cSCC and erythroplasia of Queyrat, both of which are cSCC–Bowen disease carcinoma type, unless the type of cSCC tested is specified, the results would be open to question.

Ionizing Radiation

Exposure to ionizing radiation increases the risk of developing cSCC, and the risk is directly related to the cumulative radiation dose.³ The latency period is generally approximately 30 years but may be as long as 60 years.⁴⁸ X-rays pose the greatest risk, but more superficial penetrating Grenz rays and gamma rays also cause cSCC. A variety of skin conditions, including acne, atopic dermatitis, tinea capitis, and hemangiomas were treated with ionizing radiation from 1920s to 1970s. Sunlight exposure may augment the risk of radiation-induced cSCC. Fitzpatrick skin Types I and II are at greater risk for radiation-induced skin cancer than dark skin types.⁴⁹

Immunosuppression

Immunosuppressive medications in transplant patients increase the risk 250-fold of developing cSCCs by age 65.⁵⁰ The ratio of cSCC to BCC reverses

in immunosuppressed patients, from 1 cSCC: 4 BCCs in the general population to 3 cSCCs: 1 BCC in immunosuppressed patients.^{51–54} For transplant patients, Fitzpatrick skin Type I or II and the cumulative lifetime UV exposure are the primary risk factors for the development of cSCC. Cutaneous squamous cell carcinoma usually develops within a few years after the initiation of immunosuppression,^{50,55,56} and the number of cSCCs increases with the number of years after transplantation.

The risk of cSCC development correlates with the overall aggressiveness of immunosuppressive drug regimens, that is, multiple concurrent drugs or high immunosuppressive doses per unit time. Heart transplant patients are typically treated with more aggressive immunosuppressive regimens than those with kidney transplants and have 3 times the risk of developing cSCC than kidney transplant patients.^{57,58} The mechanism by which cSCCs develop in immunosuppressed patients is unclear but may relate to a diminished capacity for immunosurveillance. CD8⁺ T cells specific for the P53 tumor suppressor gene are found in patients with cSCC.⁵⁹ Aggressive cSCCs also develop more frequently in patients with lymphoproliferative disorders such as chronic lymphocytic leukemia (CLL) that cause defects in both humoral and cell-mediated immunity.

Genodermatoses

Patients with xeroderma pigmentosum (XP) are at increased risk for cSCC because they lack an enzyme necessary for repair of DNA mutations that result from UVL and other environmental exposures.⁶⁰ In oculocutaneous albinism, patients are at increased risk of cSCC because of insufficient protective melanin.⁶¹

Clinical and Histologic Features

Actinic Keratosis and Cutaneous Squamous Cell Carcinoma In Situ–Non-Bowen Disease Carcinoma Type

The clinical hallmark of an AK and cutaneous squamous cell carcinoma in situ–non-Bowen disease carcinoma (cSCCis-NBD) is its overlying scale, which

may be subtle, feeling rough, or it may be a firm papule. An erythematous macule may be present under the scale, although at times only minimal erythema may be seen. Actinic keratoses and cSCCis-NBD vary in size from a few millimeters to one or more centimeters in diameter. Large AKs and cSCCis-NBD are likely to be slightly raised and may seem like cSCCs.

Actinic keratoses and cSCCis-NBD lesions are found most frequently on the sun-exposed skin—the head, neck, upper trunk, and extremities. These lesions are seen almost always in the presence of sun damage features such as wrinkles, additional AKs, mottled pigmentation, and telangiectasia. The lower lip is commonly affected, with partial epidermal atypia referred to as actinic cheilitis.

Actinic keratoses are characterized histologically by atypical keratinocytes with nuclear pleomorphism and irregular quantities of darkly staining cytoplasm that crowd the lower third of the epidermis. In addition, AKs usually exhibit acanthosis, hyperkeratosis, and parakeratosis; hair follicles are often spared. Full-thickness atypia with premature keratinization is termed cSCCis-NBD.

Invasive Cutaneous Squamous Cell Carcinoma–Non-Bowen Disease Type

The most common presentation of invasive cutaneous squamous cell carcinoma–non-Bowen disease type (cSCC-NBD) is an erythematous papule or nodule surmounted by scale and crust. Secondary changes can include ulceration and hyperpigmentation. On histologic examination, invasive cSCC-NBDs are categorized into well, moderately well-, moderately, and poorly differentiated subtypes. Well-differentiated cSCC-NBD arises in the setting of AK and cSCCis-NBD and has similar atypical keratinizing epidermal cells that proliferate downward in lobules and invade as detached islands into the dermis. The keratinocytes are commonly glassy, brightly eosinophilic, with prominent nucleoli. Keratin pearls and apoptotic cells are a prominent feature. As one progresses from moderately well to moderately differentiated cSCC-NBD, the degree of cell differentiation and keratinization decreases. Poorly differentiated cSCC-NBDs

are characterized by sheets or nests of poorly differentiated bizarre cells or cords of spindle cells, and cytokeratin stains may be required to diagnose the keratinocyte origin of these tumors. Poorly differentiated cSCC-NBDs have a high risk of recurrence and metastasis. Invasive cSCC-NBD may exhibit mixed cell inflammation around the tumor, sclerotic stroma, and perineural infiltration. Cutaneous squamous cell carcinoma–non-Bowen disease type that shows areas of acantholysis can be aggressive although the overall histologic pattern is well or moderately–well-differentiated. Even cSCCis-NBD with acantholysis may be regarded as potentially aggressive.^{62,63}

Cutaneous Squamous Cell Carcinoma In Situ–Bowen Disease Type

Cutaneous squamous cell carcinoma in situ–Bowen disease (cSCCis-BD) is a subtype of cSCCis that can appear clinically similar to an AK, but is suspected when the scale surmounts a thin erythematous patch, which is usually well-demarcated from the surrounding skin unlike cSCCis-NBD. Cutaneous squamous cell carcinoma in situ–Bowen disease is usually a slow-growing tumor, which arises in sun-damaged skin of the elderly and is more common in men than women.

In histologic sections of cSCCis-BD, atypical non-keratinizing epidermal cells often fill the entire thickness of the epidermis over a broad zone with more florid nuclear pleomorphism, apoptosis, and mitotic figures than that found in cSCCis-NBD type; individual cellular keratinization is absent or minimal. The epidermis may be hypertrophic or atrophic, and extension down the external hair root sheath is common.

Cutaneous squamous cell carcinoma in situ–Bowen disease type commonly occurs in hair-bearing skin, and when it occurs on the glans penis, it is known as erythroplasia of Queyrat. When cSCCis-BD is found histologically in condylomata acuminata-like lesions, it is referred to as Bowenoid papulosis.⁶⁴ Bowenoid papulosis (BP) resembles BD histologically but its atypical cells are scarce and may not be present at all depths of the epidermis.

Invasive Cutaneous Squamous Cell Carcinoma–Bowen Disease Type (Invasive Bowen Disease)

Cutaneous squamous cell carcinoma–Bowen disease (cSCC-BD) can become invasive in up to 5% of patients, metastasize in 13% to 20% of these patients,⁶⁵ and typically occurs in middle age to elderly men on the head, neck, and extremities. It presents as a rapidly growing, ulcerated tumor occurring in a scaly, or erythematous patch that was present for years. In histologic sections, one sees in the dermis islands of cells with a similar histopathologic appearance to that found in cSCCis-BD. Some keratinization may be present but it is not as prominent a feature as that seen in cSCC-NBD.

In one study of black patients,⁶⁶ BD became invasive in 26% and metastasized in 60%. It is interesting to note that, given the aggressive nature of invasive BD, current staging systems do not take this pathologic entity into account.

Keratoacanthoma

Keratoacanthoma (KA), a subtype of cSCC-NBD, may present as an erythematous nodule with a keratotic plug and usually has a volcano-like appearance. Keratoacanthomas may present with pain and inflammation and may undergo rapid growth. A KA may involute spontaneously, but it also carries a risk of enlarging with local destruction or metastasis.

Histologic examination of KA shows well-differentiated keratinocytes with glassy cytoplasm surrounding a core of cornified cellular debris. Identification on low power of a volcano-like architecture facilitates the diagnosis. Other histologic features may include lymphocytic and eosinophilic infiltrates, neutrophilic abscesses in the tumor, and elastic fiber incorporation into the tumor at its base.

Adenoid Cutaneous Squamous Cell Carcinoma

Adenoid cSCCs are rare and usually occurs on the head and neck of elderly patients. Histologically, they exhibit proliferations of well-differentiated nests of squamous cells admixed with focal or diffuse areas of tubular or pseudoglandular structures with

dyskeratotic and acantholytic cells in the lumen. These tumors have a high risk of metastasizing.^{62,63,67}

Spindle-Cell (Sarcomatoid) Cutaneous Squamous Cell Carcinoma–Non-Bowen Disease

Spindle-cell cutaneous squamous cell carcinoma–non-Bowen diseases (cSCC-NBDs) occur in areas of skin with high levels of sun exposure or previous radiation therapy. Spindle-cell cSCC-NBDs arising in areas of radiation exposure are aggressive tumors with a high metastatic risk. Histologically, they are comprised of atypical spindle cells arranged in a whirled pattern, which may infiltrate the dermis as single cells without nest or cord formation. There may be no connection to the overlying epidermis.

Desmoplastic Cutaneous Squamous Cell Carcinoma–Non-Bowen Disease

Desmoplastic or infiltrative cSCC-NBDs arise on the head and neck of elderly individuals. They are characterized histologically by cords of infiltrative spindle cells in a dense, desmoplastic stroma, which occupies at least 30% of the tumor volume. Squamous differentiation with keratin pearls is usually present.

TNM Staging of Cutaneous Squamous Cell Carcinoma–Non-Bowen Disease and Cutaneous Squamous Cell Carcinoma–Bowen Disease

The American Joint Committee on Cancer (AJCC) registry stages cSCC using the tumor/node/metastasis (TNM) classification (Table 1).⁶⁸ No differentiation is made between cSCC-NBD and cSCC-BD types of cSCC. The AJCC staging system for cSCC designates many, but not all, of the features deemed high risk in these guidelines. For instance, it does not take into account previous treatment, unusual pathologic patterns, or many anatomic areas prone to recurrence, such as the scalp. High-risk features included in the AJCC staging for the primary tumor include depth greater than 2 mm, Clark Level IV or greater, perineural invasion, location on the ear or non-hair-bearing lip, and poorly differentiated or undifferentiated histology. “T0” refers to no evidence of primary tumor, “Tis” to carcinoma in situ, “T1” is tumor 2 cm or less in greatest diameter with less than 2 high-risk

features, “T2” is tumor greater than 2 cm in diameter or of any size with 2 or more high-risk features, “T3” is invasion of maxilla, orbit, or temporal bone, and “T4” is invasion of skeleton or perineural disease at the base of the skull.

A recently described modification of the AJCC staging system for cSCC was proposed to more precisely define the T2 tumor subset of tumors with a high risk of metastasis and death.⁶⁹ Multivariate analysis of T2 tumor characteristics found that 4 high-risk factors were statistically independent prognostic factors: poor differentiation, perineural invasion, tumor diameter ≥ 2 cm, and invasion beyond subcutaneous fat. In the proposed staging system, stage T2 is stratified to those with 1 high-risk factor (Stage T2a), those with 2 to 3 high-risk factors (Stage T2b), and those with 4 high-risk factors or bone invasion (Stage T3). Stage T2b cSCCs comprised only 19% of the cohort but accounted for 72% of nodal metastases and 83% of deaths. Like the AJCC staging system, the newly proposed staging system does not take into account previous treatment.

Clinical Risk Factors for Aggressive Tumor Behavior—“High Risk” Cutaneous Squamous Cell Carcinoma

Cutaneous squamous cell carcinomas are among the most common cancers capable of metastasis. Proper management of cSCC is dependent on assessing the clinical and histologic risk factors of each tumor for aggressive growth, recurrence, and metastasis. Currently, there are no comprehensive prognostic models for high-risk cSCC because all or even most cSCC data are not recorded in registries in the United States. Furthermore, multiple risk factors often occur concurrently in individual tumors and patients, and reliable statistical modeling requires large-scale population-based studies, which have not been performed to date.

The most comprehensive data on risk factors for local recurrence and metastasis of cSCC data come from an extensive systematic review by Rowe and colleagues,²⁰ who evaluated 71 studies of recurrent and metastatic cSCC published between the years 1940 and 1990 (Table 2).

TABLE 1. AJCC TNM Staging Classification for cSCC (Seventh Edition, 2010)

<i>Primary Tumor (T)</i>			
TX	Primary tumor cannot be assessed		
T0	No evidence of primary tumor		
Tis	Carcinoma in situ		
T1	Tumor 2 cm or less in greatest dimension with less than 2 high-risk features*		
T2	Tumor greater than 2 cm in greatest dimension or tumor any size with 2 or more high-risk features†		
T3	Tumor with invasion of maxilla, mandible, orbit, or temporal bone		
T4	Tumor with invasion of skeleton (axial or appendicular) or perineural invasion of skull base		
<i>Regional Lymph Nodes (N)</i>			
NX	Regional lymph nodes cannot be assessed		
N0	No regional lymph node metastasis		
N1	Metastasis in a single ipsilateral lymph node, 3 cm or less in greatest dimension		
N2	Metastasis in a single ipsilateral lymph node, more than 3 cm but not more than 6 cm in greatest dimension; or in multiple ipsilateral lymph nodes, none more than 6 cm in greatest dimension; or in bilateral or contralateral lymph nodes, none more than 6 cm in greatest dimension		
N2a	Metastasis in a single ipsilateral lymph node, more than 3 cm but not more than 6 cm in greatest dimension		
N2b	Metastasis in multiple ipsilateral lymph nodes, none more than 6 cm in greatest dimension		
N2c	Metastasis in bilateral or contralateral lymph nodes, none more than 6 cm in greatest dimension		
N3	Metastasis in a lymph node, more than 6 cm in greatest dimension		
<i>Distant Metastasis (M)</i>			
M0	No distant metastasis		
M1	Distant metastasis		
<i>Anatomic Stage/Prognostic Groups</i>			
Stage 0	Tis	N0	M0
Stage I	T1	N0	M0
Stage II	T2	N0	M0
Stage III	T3	N0	M0
Stage IV	T1	N1	M0
	T2	N1	M0
	T3	N1	M0
	T1	N2	M0
	T2	N2	M0
	T3	N2	M0
	T any	N3	M0
	T4	N any	M0
	T any	N any	M1
<i>Histologic Grade (G)</i>			
GX	Grade cannot be assessed		
G1	Well differentiated		
G2	Moderately differentiated		
G3	Poorly differentiated		
G4	Undifferentiated		
*High-risk features for the primary tumor (T) staging—depth/invasion: >2-mm thickness, Clark level ≥IV, perineural invasion; anatomic location: primary site ear, primary site non–hair-bearing lip; and differentiation: poorly differentiated or undifferentiated.			
†Excludes cSCC of the eyelid.			

TABLE 2. Five-Year Recurrence and Metastatic Rates for Primary and Locally Recurrent cSCC as a Percentage of Determinate Cases*

<i>Treatment Modality</i>	<i>Local Recurrence Rate</i>	<i>Metastatic Rate</i>
Primary tumors of the skin (all modalities), %	N/A	5.2
Cryotherapy	N/A	N/A
ED&C	3.7	N/A
Surgical excision	8.1	N/A
Radiation therapy	10.0	N/A
Non-Mohs modalities	7.9	N/A
Mohs micrographic surgery	3.1	N/A
Non-sun-exposed skin/scar carcinoma (all modalities), %	N/A	37.9
Primary tumors of the lip (all modalities)	N/A	13.7
Non-Mohs modalities	10.5	N/A
Mohs micrographic surgery	2.3	N/A
Primary tumors of the ear (all modalities)	N/A	11.0
Non-Mohs modalities	18.7	N/A
Mohs micrographic surgery	5.3	N/A
Locally recurrent tumors (all modalities), %	N/A	30.3
Surgical excision	23.3	N/A
Mohs micrographic surgery	10.0	N/A
Recurrent tumors of the skin (all modalities), %	N/A	25.1
Recurrent tumors of the ear (all modalities), %	N/A	45.0
Recurrent tumors of the lip (all modalities), %	N/A	31.5

*Adapted from Rowe DE, et al. *J Am Acad Dermatol.* 1992; 26(6):976–90. Adaptations are themselves works protected by copyright. So in order to publish this adaptation, authorization must be obtained both from the owner of the copyright in the original work and from the owner of copyright in the translation or adaptation.

N/A, data not available.

In addition to the findings of Rowe and colleagues, the National Comprehensive Cancer Network (NCCN) guidelines⁶² for the treatment of non-melanoma skin cancer recognize the following prognostic factors important for designating tumors as high risk: anatomic location, diameter, poorly defined tumor borders, tumor recurrence, previous radiation therapy or chronic inflammation, immunosuppression, rapidly growing tumor, neurologic symptoms, poor cellular differentiation, histologic subtypes [adenoid (acantholytic), adenosquamous, desmoplastic], deep Clark level or thickness, and perineural invasion.

Two recent studies used multivariate modeling to define risk factors independently associated with a poor outcome for cSCC. In a 10-year prospective cohort study using multivariate modeling, Brantsch and colleagues²¹ found that the most important prognostic factor for metastasis was tumor depth; immunosuppression, location on the ear, and tumor

diameter >2 cm were also independently associated with a risk of metastasis. Desmoplasia and tumor thickness were risk factors for local recurrence. In a 10-year retrospective cohort study of cSCC using multivariate modeling, Schmults and colleagues¹⁹ found tumor diameter ≥ 2 cm, poor differentiation, depth of invasion beyond the superficial fat, perineural invasion, location on the ear, temple, or anogenital location contribute to poor outcome. Table 3 lists the generally agreed on risk factors for recurrence and metastasis of cSCC.

Location

Cutaneous squamous cell carcinomas located on the head and neck are more likely to recur and metastasize than those on the trunk and extremities.^{70,71} The high-risk sites mostly correspond to the “mask” areas of the face, including the central face, periocular region, eyelid, eyebrow, nose, perioral, lip (cutaneous and vermilion), chin, mandible, ear, preauricular,

TABLE 3. Risk Factors Associated With Local Recurrence and Metastasis of cSCC

Tumor characteristics
Any cSCC in high-risk sites: central face, periocular region, eyelid, eyebrow, nose, perioral, lip (cutaneous and vermillion), chin, mandible, ear, preauricular, postauricular, and temple
cSCC >1-cm diameter in intermediate-risk sites: cheeks, forehead, scalp, and neck
cSCC >2-cm diameter in any site
Poorly defined borders
cSCC exhibiting rapid growth
Neurologic symptoms
Locally recurrent cSCC after primary therapy
Histology
Depth >4 mm
Poorly differentiated
Aggressive histologic patterns: adenoid (acantholytic), desmoplastic, or spindle-cell cSCC, and invasive Bowen disease carcinoma
Perineural or vascular invasion
Host factors
Sites or previous radiation therapy
Exogenous immunosuppression (medications)
Endogenous immunosuppression (lymphoproliferative disorder, HIV)
Arising in scars or chronic wounds
Arising in sites of chronic inflammation
Genetic propensity for cSCC: XP

postauricular, and temple skin. Other high-risk areas include the dorsal hands, feet, fingers, toes, genitalia, and mucous membranes. Cutaneous squamous cell carcinomas of the scalp and ear have a high potential to metastasize. Metastatic rates for primary and recurrent cSCC of the ear have been reported to be as high as 8.8% and 45.0%, respectively, and those of the lip to be 13.7% and 31.5%, respectively.²⁰ Metastatic rates for periocular cSCC range from 10% to 25%.⁷² The cheeks, forehead, scalp, and neck are intermediate-risk sites. The trunk and extremities have the lowest risk of recurrence.

Size

The risk of recurrence and metastasis increases as tumor size increases. Data from a systematic review show that for cSCC greater than 2 cm in diameter, the local recurrence rates double (15.2% vs 7.4%) and metastatic rates triple (30.3% vs 9.1%) compared with lesions less than 2 cm.²⁰ We have generally adopted the

divisions used by others to distinguish high-risk cSCC: (1) tumors in the high-risk areas (mask areas of the face, dorsal hands, genitalia, and mucous membranes), (2) tumors in the intermediate-risk areas (cheeks, forehead, scalp, and neck) 10 mm in diameter or greater, and (3) tumors in any area 20 mm in diameter or greater.²⁸

Depth

The metastatic risk increases dramatically for lesions with a depth of 4 mm or greater or Clark Level IV or V, involvement of the reticular dermis or subcutaneous fat, or penetration into fascia, muscle, bone, or cartilage.^{21,73} Cutaneous squamous cell carcinomas from 2 to 6 mm in depth have a metastatic rate of 3%, but the metastatic rate increases to 15.5% for those with a depth greater than 6 mm or Clark Level IV or V.²¹ The metastatic risk for lip lesions greater than 6 mm in depth and skin lesions thicker than 8 mm is so high that some authors have advocated prophylactic lymph node dissection for patients with these lesions;^{74,75} some clinicians advocate head/neck imaging studies and/or sentinel lymph node evaluation. Tumors with a thickness of 10 mm or more carry a high metastatic risk, regardless of location.⁷⁶ Despite the foregoing, pathology reports rarely measure cSCC depth and except for a few recent studies, most studies do not mention tumor depth.

Poorly Defined Borders

Cutaneous squamous cell carcinomas with poorly circumscribed borders have a higher risk of recurrence than that of lesions with well-defined borders largely because subclinical tumor extension may result in higher rates of treatment failure.^{20,70,71}

Rapid Growth

One study on the growth rate of cSCCs of the ear or eyelid found that rapidly growing lesions metastasize in up to one-third of cases compared with a rate of 5% to 10% in slower growing lesions.⁷⁷

Histologic Differentiation

Patients with poorly differentiated cSCCs have a worse prognosis than those with well-differentiated

tumors.^{20,78} A systematic review showed that poorly differentiated cSCCs had a local recurrence rate of 28.6%, whereas well-differentiated tumors recur at a rate of 13.6%.²⁰ The presence of infiltrating tumor cell strands of tumor cells, presence of single cells, small tumor nests, and acantholysis are associated with a high rate of metastasis.^{74,79–82} Sometimes tumors show both well-differentiated and poorly differentiated features and thus become difficult to categorize.

Histologic Subtype

Histologic cSCC subtypes that have an increased risk of recurrence or metastasis are adenoid, desmoplastic, spindle-cell, and invasive cSCC-BD type.^{21,65,83–87}

Perineural Invasion

Cutaneous squamous cell carcinomas that exhibit perineural invasion may have a poor prognosis.^{88,89} The progressive movement of tumor cells along nerve fibers or the neurovascular bundle allows tumors to spread great distances. Furthermore, perineural invasion may not be evident clinically or histologically until there is extensive local nerve fiber invasion.³ The diameter of the involved nerves substantially affects the outcome. One study showed that involvement of nerves <0.1 mm in diameter had no disease-specific deaths, compared with a 32% mortality rate, when nerves 0.1 mm or more in diameter were affected.⁸⁹ A study⁹⁰ suggested that large-caliber (≥ 0.1 mm) nerve invasion is associated with an increased risk of nodal metastasis and death, but this was not substantiated with multivariate analysis because the study was underpowered for an analysis of this risk factor. Nevertheless, a single small caliber nerve with cSCC invasion does not seem to affect the prognosis.

Neurological Symptoms and Signs

Symptoms and signs consistent with involvement of sensory or motor nerves including pain, burning, anesthesia, paresthesia, diplopia, blurred vision, and facial paralysis^{3,91} may occur in up to 40% of patients with perineural invasion. Symptomatic perineural invasion is associated with unresectable disease and a poor outcome.⁹²

Recurrence

A recurrent cSCC is more likely to recur and metastasize regardless of treatment. For instance, in one study,²⁰ the local recurrence rate was 8.1% for excision of primary cSCCs compared with a 23.3% recurrence rate for excision of recurrent cSCCs. In the same study, primary cSCC had a metastatic rate of 5.2% after treatment by any modality but a 25.1% metastatic rate if a recurrent cSCC. Both a decrease in disease-specific survival and an increase in the metastatic rate have been shown in other studies for recurrent cSCCs.^{79,93}

Scar Carcinoma (Marjolin Ulcer)

Cutaneous squamous cell carcinomas that arise in long-standing injured skin, such as scars, ulcers, or sinus tracts, have a metastatic risk of up to 40%.^{20,43,94} Aggressive cSCCs are common in EB and nearly 80% of those with recessive dystrophic EB–Hallopeau-Siemens subtype die of metastatic cSCC.^{95,96}

Immunosuppression

The overall metastatic rate from cSCC in patients receiving long-term immunosuppression for organ transplants exceeds 12%.^{54,55,58,80,97} Patients treated with immunosuppressive agents for other medical disorders also develop cSCC at high risk for recurrence and metastasis.²⁰ Aggressive cSCCs are also more commonly found in patients with endogenous causes of immunosuppression including leukemia (especially CLL), lymphoma, epidermodysplasia verruciformis, and cutaneous T-cell lymphoma. Recurrence of cSCC after Mohs surgery in patients with CLL is 7 times more likely compared with controls.⁹⁸

History of Radiation Treatment

Cutaneous squamous cell carcinomas arising in areas of previous radiation treatment recur more frequently and metastasize at a rate of 10% to 30%.^{3,43,44,79,80,99} One explanation to explain the high recurrence and metastatic rate is delay in diagnosis. Cutaneous squamous cell carcinomas that arise in an area of radiation treatment may present as an ulcer and are often misdiagnosed as radiation necrosis. Ulcerations

that develop in areas of radiation treatment that fail to respond to conventional medical therapy should therefore be biopsied.

Clinical Evaluation

Evaluation of a patient with cSCC requires lesion history, medical history, and physical examination. A history should be obtained about previous skin cancers, family history of skin cancer and other cancers, estimated lifetime cumulative sun exposure, arsenic exposure, smoking, carcinogenic occupational exposures, previous radiation, and potential causes of immunosuppression. A complete skin examination is suggested because individuals with one skin cancer often have additional skin cancers or precancerous skin lesions at other sites, and they are at increased risk of developing malignant melanoma.¹⁰⁰ A regional lymph node examination should be performed in all patients with cSCC. A skin biopsy of suspicious lesions is performed and should include the deep dermis if an indurated or nodular lesion is present. Suspicious lesions are often difficult to follow clinically in high-risk patients with multiple skin cancers and AKs. Photographs or digital images are recommended for documenting the location and appearance of specific lesions, and there should be a low threshold for obtaining skin biopsies in high-risk patients.

If a palpable lymph node is present in a patient with cSCC, or abnormal lymph nodes are found by imaging studies, a fine-needle aspiration (FNA) for cytopathologic examination should be considered. If the FNA is negative, repeat imaging, repeat FNA, or open lymph node biopsy should be considered, particularly because FNA can produce falsely negative results in some clinical situations such as in patients with a history of previous radiation.¹⁰¹ In patients with positive lymph node biopsies, appropriate imaging studies are obtained to determine the extent of local lymph node involvement and rule out distant disease.

Preoperative imaging studies should be obtained when there is suspicion of metastases, bone invasion, or perineural infiltration. The sensitivity of clinical lymph node examination is rather low, at 72%.¹⁰² The sensitivity rises to 91% when computed tomography (CT)

and magnetic resonance imaging (MRI) are performed. Controversy exists regarding the choice of radiologic examination. Computed tomography is used to image extracapsular spread, central nodal necrosis, bone, skull base, and cartilage invasion. Magnetic resonance imaging provides improved imaging of tissue planes and neurotropic tumors.¹⁰³ Positive emission tomography can detect metastases, especially in areas of necrosis, dense fibrosis, or scarring from radiation therapy, whereas both CT and MRI can identify soft tissue infiltration and bony erosion.¹⁰⁴

Selection of Therapy

In choosing a therapy for primary cSCC, the goals are the following: to completely extirpate the tumor, to minimize the risk of recurrence and metastasis, to restore normal function after treatment, and to provide the best possible aesthetic outcome. Maximal normal tissue preservation becomes paramount when large surgical defects will compromise normal function or produce disfigurement and when extensive areas of skin are involved in high-risk patients. The cure rate, however, remains the main consideration in choosing therapy. The systematic review by Rowe, Carroll, and Day of 50 years of medical literature contains the largest compiled dataset available to date assessing outcomes based on treatment method for both primary and recurrent cSCC²⁰ (Table 3).

It cannot be overemphasized that the best chance for cSCC cure is in the first treatment of the initial lesion, as all tumor treatment options are less successful for persistent or recurrent tumors than for primary tumors (Table 3). Once a cSCC has recurred, the risk of spread to regional lymph nodes and distant metastases increases significantly, from 25% to 45% in high-risk area.^{20,79} High-risk tumors therefore require treatment with Mohs micrographic surgery (MMS), which offers complete, circumferential, and deep margin control. When MMS is unavailable, excision with complete peripheral and deep intraoperative frozen section assessment is the best alternative.

Low-risk cSCCs have a high cure rate when treated with excision with intraoperative and postoperative

pathological analysis (“standard surgical excision,” SSE), electrodesiccation and curettage (ED&C), and cryosurgery.^{105,106} Likewise for small cSCCs (both cSCCs-BD and cSCCs-NBD types) in low-risk areas with no high-risk pathologic features, non-Mohs modalities are generally acceptable treatment options.

The choice of therapy should be assessed individually in every patient. Additional factors that should be considered include the patient’s general medical condition and psychosocial circumstances, such as the ability to return for additional treatment and whether the tumor is in a cosmetically sensitive location.

Because there is a wide range in fees depending on the procedure used and the site of service, cost is another important factor in choosing the most appropriate treatment. A detailed discussion of the cost analysis is provided in Section XIII.

Mohs Micrographic Surgery

Mohs micrographic surgery provides the best long-term cure rate for any cSCC and is the treatment of choice for high-risk and recurrent cSCC because of its complete margin assessment and tissue-sparing benefits.^{3,20,107} The high cure rate is achieved because almost 100% of the tissue margins (both peripheral and deep) are examined with MMS, compared to standard vertical sectioning, in which less than 1% of the outer and deep margins are examined. The NCCN guidelines⁶² for the treatment of high-risk cSCC recommends Mohs surgery to ensure complete circumferential and deep margin assessment to achieve the best cure rate. Table 4 is based on the appropriate use criteria (AUC) for MMS developed jointly by the American Society for Dermatologic Surgery, the American Academy of Dermatology, the American College of Mohs Surgery, and the American Society for Mohs Surgery (<http://www.aad.org/education-and-quality-care/appropriate-use-criteria/mohs-surgery-auc>¹⁰⁸). The AUC included an extensive analysis of the literature that met evidence-based criteria. After this review was completed, 143 case scenarios were created for cSCC and voted on for the appropriateness of using MMS. Those physicians who ranked the case scenarios included not only dermatologists who perform MMS but mostly dermatolo-

gists who do not perform MMS. Thus, the ultimate scoring was a blend of both published data and clinical experience.

Based on the AUC guidelines, MMS is appropriate for (1) cSCCs in the high-risk areas that include the central face, eyelids, canthi, eyebrows, nose, lips, chin, ear, periauricular areas, temples, hands, feet, ankles, fingers, toes, genitalia, perianal, nipples/areola, and mucous membranes, (2) cSCCs in the intermediate-risk areas including cheeks, forehead, scalp, jawline, neck, and shin, and (3) cSCCs in low risk areas with diameters ≥ 2 cm in healthy patients and ≥ 1 cm in immunocompromised patients, (4) cSCC and cSCCs that are present in areas of chronic inflammation, osteomyelitis, previous radiation, or scar, locally recurrent and incompletely excised cSCC and cSCCs, and cSCCs that develop in immunosuppressed patients or in patients with genetic syndromes. Mohs micrographic surgery is also indicated when the following histologic features are present in cSCC: (1) depth of 2 mm or greater or Clark Level IV or V, (2) poorly or undifferentiated tumors, (3) adenoid, pagetoid, small cell, basosquamous, single cell, clear cell, lymphoepithelial, adenosquamous (mucin-producing), desmoplastic, sclerosing, infiltrating, sarcomatoid, and spindle-cell subtypes, and (4) those with perineural or vascular invasion. The AUC guidelines did not address tumors with ill-defined margins, rapidly growing tumors, acantholytic cSCCs,⁶² or invasive cSCC-BD,^{65,66} but MMS is certainly an excellent option for these tumors as well. Mohs micrographic surgery is also the optimal treatment when tumors are located in areas where maximal preservation of normal tissue is preferred or required.

The Rowe and colleagues²⁰ study data demonstrate that MMS provides the highest cure rates for both primary and recurrent cSCCs of the skin, lip, and ear (Table 3). The reported 5-year local recurrence rates for primary skin cSCCs were 7.9% for non-Mohs modalities and 3.1% for MMS. Because the more aggressive, high-risk tumors are preferentially treated with MMS, the reported recurrence rates for some non-Mohs modalities, particularly for ED&C at 3.7%, which is reserved for low-risk, small (<1 cm) tumors,

TABLE 4. Appropriate Use Criteria for the Treatment of cSCC by Mohs Micrographic Surgery¹¹⁰

<i>Tumor Type*</i>	<i>Area H</i>	<i>Area M</i>	<i>Area L</i>
Primary cSCC with no high-risk† features healthy patients	Mohs appropriate	Mohs appropriate	Mohs appropriate (if >2.0 cm)‡
Primary SCC with no high-risk† features immunocompromised patients	Mohs appropriate	Mohs appropriate	Mohs appropriate (if >1 cm)‡
Verrucous cSCC healthy and immunocompromised patients	Mohs appropriate	Not assessed	Not assessed
SCC, KA type healthy patients	Mohs appropriate	Mohs appropriate	Mohs appropriate (if >1.0 cm)‡
cSCC, KA type immunocompromised patients	Mohs appropriate	Mohs appropriate	Mohs appropriate (if >0.5 cm)
cSCCIS/Bowen disease carcinoma healthy patients	Mohs appropriate	Mohs appropriate	Mohs appropriate (if >2.0 cm)‡
cSCCIS/Bowen disease carcinoma immunocompromised	Mohs appropriate	Mohs appropriate	Mohs appropriate (if >1.0 cm)‡
Recurrent cSCC (all types) or other high-risk features† healthy or immunocompromised patients	Mohs appropriate	Mohs appropriate	Mohs appropriate‡§
Aggressive (high risk) cSCC† healthy and immunocompromised patients	Mohs appropriate	Mohs appropriate	Mohs appropriate

Area H: central face, ears, genitalia, hands, feet, pretibial.
 Area M: cheeks, forehead, scalp, neck.
 Area L: trunk, extremities except hands, feet, pretibial.
 *Tumor type excludes actinic keratosis and cSCCis–non-Bowen disease type.
 †Aggressive cSCC indicates tumors with high-risk histologic features including the following: sclerosing, basosquamous, small cell, poorly or undifferentiated, spindle cell, pagetoid, infiltrating, KA (centrofacial), single cell, clear cell, lymphoepithelial, sarcomatoid, Breslow depth 2 mm or greater and Clark level IV or greater.
 ‡Mohs surgery is indicated for any size tumor with special patient features including the following: previous radiated skin, genetic syndromes, osteomyelitis, a history of aggressive-behaving tumors, chronic ulcer, inflammation, and traumatic scar.
 §Except for cSCCis–Bowen disease type (Bowen disease carcinoma) ≤2.0 cm.

are likely to be underestimated compared with those for MMS. For primary cSCC of the lip, 5-year recurrence rates were 10.5% for non-Mohs modalities and 2.3% for MMS. For primary cSCC of the ear, 5-year recurrence rates were 18.7% for non-Mohs modalities and 5.3% for MMS. Surgical excision of locally recurrent cSCCs has a 5-year recurrence rate of 23.3% compared with 10.0% for lesions treated with MMS.

Adverse Effects

Mohs micrographic surgery is a very safe outpatient procedure. In a study of 3,937 consecutive patients undergoing Mohs surgery, the only serious surgical complication was gastrointestinal hemorrhage because of naproxen prescribed postoperatively for an unrelated problem.¹⁰⁹ The overall complication rate was 1.64% in a prospective study of 1,358 cases of MMS.¹¹⁰ Most surgical complications involved difficulties with hemostasis and none were signifi-

cant enough to involve the assistance of another specialist or to require the hospitalization of the patient.

Advantages

Mohs micrographic surgery has the highest cure rates for both primary and recurrent cSCC. For locally recurrent tumors, the 5-year cure rate for MMS is 90.0% compared with 76.7% for SSE.²⁰ Because MMS is a tissue-sparing technique, smaller surgical margins are taken and scarring and functional impairment are minimized compared with SSE and ED&C. Tumor removal and reconstruction are usually performed on the same day, using local anesthesia in an office-based setting.

Disadvantages

The primary disadvantage of Mohs surgery is its expense when compared with ED&C, but the cost of

MMS compares favorably with SSE when the cost of pathology, the savings of re-excisions to obtain clear margins, and the savings of treating fewer recurrences are factored in.¹¹¹ Mohs micrographic surgery in the office setting is significantly less expensive than SSE with frozen section margin control in an ambulatory surgery center (ASC) or hospital operating room. Furthermore, MMS in a “hospital-based facility” (a hospital owned—nonoperating room) would add an additional unnecessary cost (Section XIII).

Standard Surgical Excision

Standard surgical excision consists of surgical excision followed by postoperative pathologic analysis with permanent sections and is used for low-risk cSCC. For well-circumscribed tumors with diameters less than 2 cm that do not occur on the ears, lips, eyelids, nose, or scalp and do not invade the fat, margins of 4 to 6 mm are usually adequate to achieve a 95% chance of a cure.^{20,62,112} For lesions with diameters of 2 cm or greater a 9 mm margin or greater may be required for total tumor extirpation,¹¹² but tissue rearrangement should not be performed until pathologic verification of tumor-free margins is ascertained. Larger initial margins are often required with SSE than with MMS to increase the likelihood of complete tumor removal and thus SSE may result in a larger surgical defect and larger scar than that achieved by MMS.

Adverse Effects

The risk of infection and hematoma formation is low.

Advantages

Compared with ED&C, SSE offers the advantage of rapid healing and improved cosmetic results, as with MMS. Unlike destructive or topical modalities, there is histologic analysis of the excised tissue specimen. If the cSCC is excised in one procedure in an office setting, the cost may be less than for MMS.

Disadvantages

The cure rates for SSE are similar to ED&C, despite the histologic verification of tumor margins, most likely because the traditional “breadloafing” or “cross”

method to process the surgical specimen enables examination of less than 1% of the margins.

Radiation Therapy

A wide variety of radiation treatment modalities and dosages have been used, with irradiation techniques being adapted to tumor characteristics, such as location and size, and available equipment.^{113–116} External beam radiation has been the most studied modality. The reported 5-year control rates for cSCC treatment with external beam radiation are 80% for cSCC.¹¹³ Recurrent tumors have a higher re-recurrence rate than that of primary tumors and might pose a particular therapeutic challenge to any subsequent treatment because of local destruction of cutaneous vasculature. Irradiated tissue renders wound healing with subsequent surgery difficult and largely eliminates a second course of radiation as a treatment option. Thus, radiation therapy as a primary treatment modality for cSCC is best reserved for those situations in which surgical risk is not acceptable. Radiation therapy is generally reserved for patients more than 50 years because of the potential for tumor induction at a later time, usually 20 to 30 years later.¹¹⁷ Radiation therapy may be considered when tissue margins are positive after MMS, and further surgery is contraindicated.

Brachytherapy is becoming a popular method with which to treat cSCC. This method requires the radiation source to be a short distance from the tumor. There are 2 types of brachytherapy: radioactive isotope brachytherapy and electronic brachytherapy.^{118,119} Radioactive isotope brachytherapy requires that a radioactive isotope, usually iodine-131 or iridium-192, be placed on or within the tissue. Electronic brachytherapy is a 50 kV x-ray device that places the source of the x-rays very close to the tumor by applicators. It is very similar to contact x-ray devices used years ago by dermatologists. Electronic brachytherapy is being performed in fewer treatment sessions than those with superficial or electron beam therapy. The inherent limitation of electronic brachytherapy is that the x-rays penetrate only a short distance into tissue and one designs the treatment based on a calculated assumption of tumor depth and breadth. The long-term cure rate of BT is not known

and no standard protocols have been tested prospectively. Although cure rates of up to 90% are reported,¹¹⁹ in the absence of long-term follow-up studies, reports of cure may be overestimated. Furthermore, the long-term cosmetic results of electronic brachytherapy are unknown, but based on results of superficial x-ray, cosmetic deterioration would be expected to begin 5 years after radiotherapy. Furthermore, with fewer fractionations (usually 8) rather than the standard number (16), cosmetic deterioration is more likely with time.

Adverse Effects

Potential adverse effects of radiation therapy include desquamation, alopecia, atrophy, telangiectasia, pigmentary alteration, fibrosis, ectropion, parotiditis, mucositis, soft tissue or bone necrosis, radiodermatitis with nonhealing ulcerations, ocular damage, hearing loss, and secondary skin malignancies decades after treatment.¹²⁰

Advantages

Radiation therapy is sometimes preferred by patients who wish to avoid surgery or in the patient for whom surgery is contraindicated for medical reasons. Radiation therapy is occasionally recommended as a primary treatment when surgery will compromise function by sacrificing major nerves or other vital structures; it may also be useful if there is perineural invasion by cancer cells or for tumors that are surgically unresectable.

Disadvantages

Radiation therapy is the most expensive treatment method and usually requires 15 to 30 patient visits because radiation doses must be fractionated to minimize scarring, radiodermatitis, and skin breakdown. Electronic brachytherapy in particular is very expensive, nearly 5 or 6 times the cost of superficial x-ray treatments. Radiation therapy is contraindicated in patients with XP because of their risk of developing ionizing–radiation-induced malignancies as a result of impaired DNA repair mechanisms.^{60,114,115} Recurrence rates are significantly higher after radiation therapy than after MMS for both primary and recurrent cSCCs. The cSCCs that recur after radiation therapy tend to be highly infil-

trative and aggressive. Cosmesis at 4-year follow-up was better for lesions treated with surgery compared with radiation therapy in one randomized study.¹²¹ Histologic confirmation for complete tumor destruction with radiation therapy is generally not done.

Electrodesiccation and Curettage

Electrodesiccation and curettage should be considered for the treatment of low-risk well-circumscribed primary cSCCs with diameters less than 1 cm, present on the trunk, arms, or legs.^{105,122} For other cSCCs, the risk of recurrence and metastasis after ED&C is unacceptably high. Electrodesiccation and curettage should not be used for tumors present on terminal hair-bearing skin because of the risk of tumor extension along follicular structures. Such follicular extension is particularly a problem with cSCCis-BD. If the subcutaneous layer is reached during the ED&C procedure or the biopsy results obtained from the curettage reveal a high-risk histological subtype, SSE or Mohs surgery is recommended.

Adverse Effects

Wounds from ED&C typically have longer healing times than excisional wounds and often leave a white scar that can sometimes be atrophic or hypertrophic.

Advantages

Electrodesiccation and curettage is the least expensive method to treat BCC.

Disadvantages

Electrodesiccation and curettage often produces a white, atrophic, or hypertrophic scar, which can be cosmetically unacceptable to many patients, and the recurrence rates are excessively high for high-risk cSCC. There is no histologic confirmation of complete tumor clearance.

Cryotherapy

Cryotherapy involves the controlled, careful application of liquid nitrogen to the clinically visible tumor and surrounding skin.^{123,124} If this procedure is performed precisely for large tumors, a temperature probe is inserted tangentially just lateral to the lateral margin of the tumor and its tip is placed deeply below

the middle of the tumor. Then, liquid nitrogen is applied to the lesion until a temperature of -60°C on the temperature probe is reached. Cryosurgery should be considered only for small (<1 cm), low-risk cSCC and cSCCis because of the low cure rates achieved when the technique is used for high-risk tumors.¹²⁵

Adverse Effects

Patients experience pain and swelling after the treated area thaws. An eschar usually develops after treatment and persists for approximately 4 to 6 weeks. Permanent pigment loss, atrophy, and hypertrophic scarring are common. Motor and sensory neuropathies are infrequent complications but are of concern when liquid nitrogen is applied to tumors overlying nerves where the dermis is thin such as on the digits.

Advantages

Cryosurgery is a rarely used, low-cost procedure for small, well-defined, low-risk cSCCs or for large cSCCs when patients are unable to undergo surgery or radiation therapy.

Disadvantages

The success of the procedure is operator-dependent and the overall recurrence rates are high for primary and recurrent cSCCs.²⁰ Scarring is unpredictable and may be cosmetically inferior to other treatment options. There is no histologic confirmation of complete tumor clearance.

Topical Therapy

Three topical medications, 5-Fluorouracil cream (Efudex; Valeant Pharmaceuticals International, Bridgewater, NJ), Imiquimod cream (Aldara; Medicus Pharmaceuticals, Scottsdale, AZ), and ingenol mebutate (Picato; Leo Pharma, Parsippany, NJ), are Food and Drug Administration (FDA) cleared for the treatment of AKs and may be considered for the treatment of cSCC under special circumstances. The cure rate of cSCCis treated with 5% 5-fluorouracil (5-FU) cream is poor, with a 48% to 69% clearance rate at 1 year after a treatment program of once daily application for 1 week followed by twice daily application for 3 weeks.^{126,127} Imiquimod may stimulate innate and acquired immunity by inducing transcription of interferon alpha and gamma, and tumor

necrosis factor alpha after binding to Toll-like receptor 7. One randomized controlled study evaluating the efficacy of daily application of imiquimod for 16 weeks for cSCCis-BD resulted in a 73% (11/15) complete response rate as determined by the examination of shave biopsy specimens at 12 weeks after treatment.¹²⁸ In a study of cSCCis-BD greater than 1 cm in diameter treated with daily application of imiquimod for 16 weeks, only 10 of 16 subjects completed therapy because of adverse skin reactions, including 4 with *Staphylococcus aureus* colonization. There was an 87.5% cure rate (14/16) at 6 weeks determined by incisional biopsy.¹²⁹ A new topical cream, ingenol mebutate, has been FDA approved for the treatment of AKs, but not cSCCis or invasive cSCC although it has showed benefit treating cSCC in a mouse model.¹³⁰ Ingenol mebutate is believed to exert its effect through primary necrosis and activation of the immune system. It should be pointed out that in the United States, the topical creams 5-FU, imiquimod, and ingenol mebutate are not approved for the treatment of cSCC.

There are few studies of other topical treatments for cSCC and follow-up is limited. Higher-percentage strengths of trichloroacetic acid (30%–35% on the face and 40%–50% on scalp and extremities) for broader areas of involvement, for patients who tolerate cryotherapy poorly, or for those who have difficulty affording prescription topical agents are another topical alternative for superficial cSCCis.

Adverse Effects

Application site reactions are common, dose-dependent and include pruritus, erythema, edema, pain, hyperpigmentation, hypopigmentation, bleeding, crusting, and erosions. Systemic reactions occur rarely with imiquimod and include flu-like symptoms, arthralgia, myalgia, fatigue, and lymphadenopathy.

Advantages

5-Fluorouracil, imiquimod, or ingenol mebutate¹³¹ can be used off-label in patients who do not want surgery or those who are poor surgical candidates for cSCCis, and these are excellent modalities for the treatment of field cancerization after the surgical removal of

invasive cSCCs. 5-fluorouracil is relatively inexpensive and the cost of treatment is low.

Disadvantages

5-fluorouracil, imiquimod, and ingenol mebutate creams frequently produce local side effects lasting 1 to 3 weeks. The cost of treatment with imiquimod is comparable to surgery and the cure rates with either cream (5-FU or imiquimod) are lower than those with surgical methods. There is generally no histologic confirmation of complete tumor clearance.

Photodynamic Therapy

Photodynamic therapy involves the application of a photosensitizing agent on the skin followed by irradiation with a light source.¹³² Photodynamic therapy using 20% topical aminolevulinic acid (ALA) in combination with a blue light source and the methyl ester of ALA (MAL) under occlusion in combination with a red light source is approved by the FDA for the treatment of AKs. There are multiple studies using a wide variety of treatment regimens evaluating the efficacy of PDT for the treatment of nonmelanoma skin cancer. In studies of ALA and MAL-PDT for the treatment of cSCCis-NBD, the recurrence rates range from 0% to 66%.¹³³ In a randomized controlled trial of MAL-PDT (3 hours incubation, red light 570–670 nm, 75 J/cm²) versus cryotherapy or topical 5-FU for cSCCis-NBD, there was a complete response in 93% (103/111) with MAL-PDT, 83% (24/29) with 5-FU, and 85% (73/85) with cryotherapy. Recurrence rates at 1 year were 15% for MAL-PDT, 17% for 5-FU, and 21% for cryotherapy.¹²⁷ In an open-label study of 6 invasive cSCCs treated with a series of 4 ALA-PDT every other day, histopathologic resolution was observed in only 2 of 6 (33%) lesions at a median follow-up time of 29 months.¹³⁴ Cyclic PDT with 5-ALA given to solid organ transplant recipients (SOTRs) at 4-week to 8-week intervals for 2 years reduced the incidence of cSCC.¹³⁵ The study showed that PDT with 5-ALA may be beneficial as a preventive measure in SOTRs.

Adverse Effects

There is pain and stinging during treatment with PDT. The pain has been dramatically lessened, though, by

reducing the incubation period from 14 to 18 hours down to 1 to 3 hours. Erythema and edema develop immediately after treatment and may last for up to 1 week. Other side effects include crusting, blistering, oozing, and bleeding.

Advantages

Although the cure rates for PDT are lower than those with surgery for individual lesions, the reported advantage over surgery is better cosmesis. Broad areas of skin or multiple AKs and cSCCis-NBD may be treated in 1 session when “field cancerization” is suspected.

Disadvantages

Particular light source equipment is required for therapy. Patients remain photosensitive to visible light for a period of 24 to 48 hours after treatment. Tumor clearance rates are lower than with some other treatment modalities. There is no histologic confirmation of complete tumor clearance.

Synthesis of Literature Regarding Treatment of Cutaneous Squamous Cell Carcinoma

The analysis of the different treatment options for cSCC took into account selected published cure rates and the advantages, disadvantages, and adverse effects of each treatment type. An algorithm that reflects these parameters and is consistent with the AUC guidelines is shown in Figure 1. High-risk tumors require treatment with MMS, which offers complete, circumferential, and deep margin control. When MMS is unavailable, excision with complete peripheral and deep intraoperative frozen section assessment is the best alternative.

Low-risk cSCCs have a high cure rate when treated with excision with intraoperative and postoperative pathological analysis (“standard surgical excision”), C&E, and cryosurgery.^{105,106} Likewise for cSCCis (both cSCCis-BD and cSCCis-NBD types) with no high-risk features, non-Mohs modalities are generally acceptable treatment options.

Follow-up

Frequent follow-up visits are recommended for patients with a history of invasive or high-risk cSCC to monitor for tumor recurrence and metastasis and for

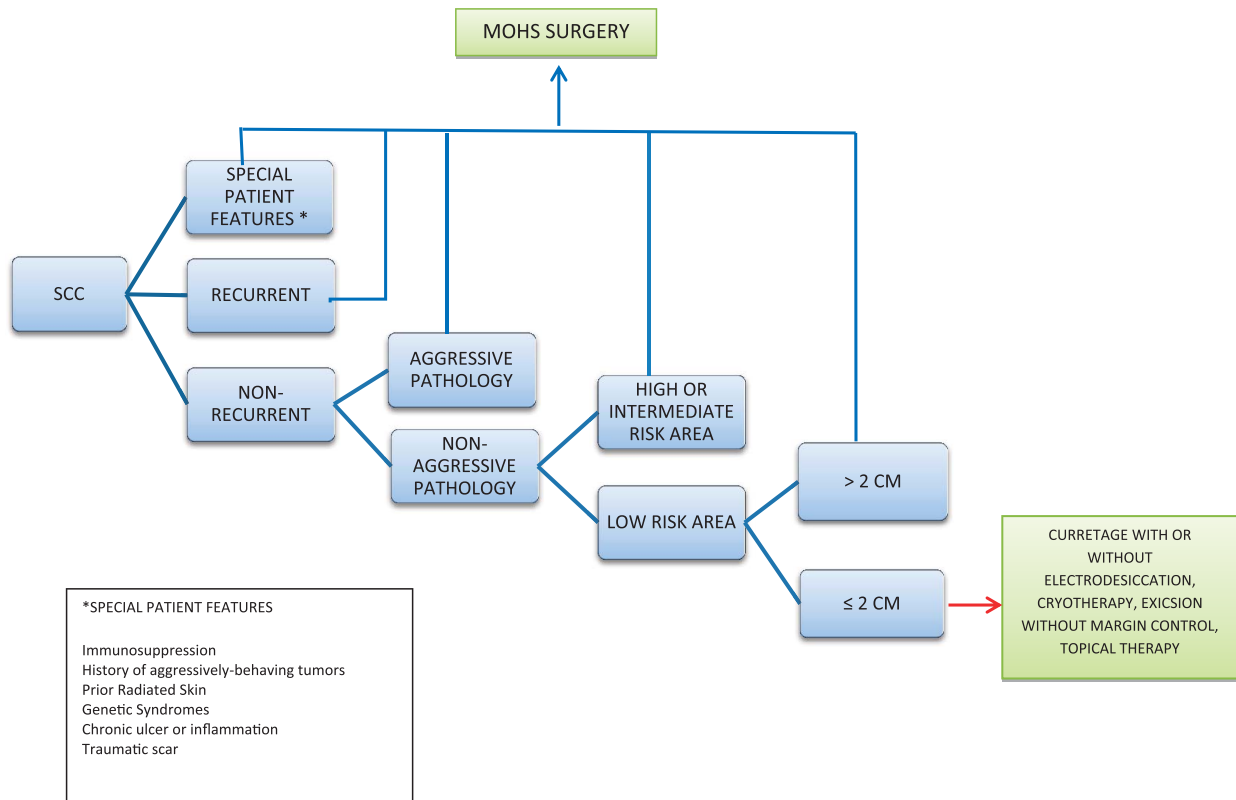


Figure 1. Algorithm for squamous cell carcinoma† treatment. †Excludes actinic keratosis (cSCC is non-Bowen disease type); high-risk areas (central face, ears, genitalia, hands, feet, and pretibial); intermediate-risk areas (cheeks, forehead, scalp, neck); low risk-areas (trunk, extremities except hands, feet, pretibial).

the development of new lesions of NMSC and malignant melanoma.^{39,40,136} Those with local disease should have a full skin and lymph node examination every 3 to 6 months for the first 2 years, every 6 to 12 months for the next 3 years, and annually thereafter. Patients with endogenous or exogenous causes of immunosuppression or a genetic predisposition to cSCC, as in those with XP, require more extensive evaluation, increased surveillance, and prophylactic measures. Recommended follow-up for regional metastatic disease is every 1 to 3 months for the first year, every 2 to 4 months for the second year, every 4 to 6 months up to 5 years, and then every 6 to 12 months thereafter. A multidisciplinary tumor board should be consulted for patients with complicated, high-risk cSCCs, and regional or distant spread.

The rationale for frequent follow-up visits after cSCC treatment is patients with 1 cSCC have a 30% to 50% risk of another NMSC within 5 years and are at increased risk for malignant melanoma.^{39,40,136} Approximately 75% of local cSCC recurrences and metastases occur

within 2 years of diagnosis and 95% occur within 5 years of primary diagnosis. Patients with cSCC require a lifetime of monitoring, but more vigilant follow-up is required during the initial 2 years after diagnosis.

Special Treatment Considerations

Perineural Invasion

When involvement of a large nerve is suspected, an MRI and CT should be obtained to evaluate the extent of disease and rule out intracranial involvement.¹³⁷ The risk of spread is significantly decreased when the affected nerve is carefully dissected to obtain tumor-free margins. Historical rates of metastasis for cSCC exhibiting perineural invasion are as high as 47%, but the rate of metastasis is significantly lower (8%) when Mohs surgery is used.²⁰

Radiation therapy is recommended as adjuvant therapy for cSCC with substantial perineural involvement.⁹¹ The lack of precise prognostic estimates for

cSCCs with different degrees of nerve invasion adjusted for other concomitant risk factors prevents clear guidance on the clinical approach to cSCC with perineural invasion. This is reflected in the diversity of management, as evidenced in a study of Mohs surgeons, in which there was little consensus regarding when adjuvant radiation should be used.¹³⁸

Regional or Nonregional Lymph Node Disease

Spread of cSCC occurs through one or several routes, that include extensions along fascial planes or neurovascular bundles, blood vessels (arteries, veins, lymphatics), and nerves. Most head and neck cSCCs spread to the ipsilateral facial, cervical or intraparotid lymph nodes. Regional metastases to the parotid parenchyma or contralateral lymph nodes can also be detected. Regional nodal involvement from cSCC significantly increases the risk of recurrence and death.^{139,140} When lymph node involvement is confirmed by FNA or open biopsy, regional lymph node dissection is advisable. Postoperative radiation therapy is recommended for all patients with nodal involvement in the head and neck region.^{138,141–145} When the lymph node disease is deemed inoperable, radiation therapy with or without cisplatin is recommended; after radiation treatment, the patient should be re-evaluated for suitability for lymph node resection. Chemotherapy should be considered in cases with residual positive margins and extracapsular extension.¹⁴⁶ At least a superficial parotidectomy is required if there is spread through the parotid fascia into the parenchyma of the parotid gland.¹⁴⁷

The role of sentinel lymph node biopsies (SNLBs) for high-risk cSCC remains in evolution. It may be underutilized in cSCC because reports to date show about a 20% SLNB positivity rate, which is much higher than most melanoma series,¹⁴⁸ and early detection may positively impact survival. There are no widely accepted criteria and, at the present time, SNLB for cSCC is probably best considered on a case-by-case basis.

There is limited data on the efficacy of chemotherapy for metastatic disease.^{149,150} Cisplatin has been used alone or in combination with 5-FU, methotrexate, bleomycin, or doxorubicin. Capecitabine is an oral prodrug of 5-FU that is metabolized to 5-FU within

tumor cells and has fewer adverse effects than systemically administered 5-FU. Epidermal growth factor receptor (EGFR) inhibitors, including cetuximab and gefitinib, have been used off-label to treat metastatic cSCC because of the overexpression of EGFR in some tumors. Results for regimens with these drugs are mixed. There are ongoing phase II and III trials for various combination chemotherapy regimens. Randomized trials of isotretinoin have shown no benefit for the treatment of existing tumors.

Immunosuppressed Patients and Cutaneous Squamous Cell Carcinoma

Patients with solid organ transplantation have up to 250-fold increased incidence of cSCC,⁵⁰ and as the duration and dosage of the immunosuppression increases, the rate of cSCC formation increases.¹⁵¹ Transplant patients taking T-cell inhibitors such as cyclosporine have a 2.8-fold higher incidence of cSCC than patients on only azathioprine and prednisone. Sirolimus, an inhibitor of the mammalian target of rapamycin is a newer calcineurin inhibitor with antiangiogenic properties that is associated with a lower incidence of cSCCs in organ transplant recipients.¹⁵²

For patients who can tolerate it, oral retinoids (such as isotretinoin, acitretin, etc.) have been shown to reduce the rate of new skin cancer formation. However, reducing or stopping the retinoid leads to a rebound in new skin cancer growths that may be difficult to manage. Imiquimod can be used as part of the patient's treatment regimen as it does not seem to have an adverse effect on the transplant, but it may cause flu-like symptoms when used over large surface areas because of systemic absorption.

The development of multiple aggressive cSCCs should prompt an evaluation of the patient's immune status. In patients with lymphoproliferative disorders such as CLL, this often indicates disease progression.¹⁵³

Management of High-Risk Patients and Field Cancerization

Patients who are at risk for the development of multiple or aggressive cSCCs are broadly defined as

“high-risk.” These include patients with either endogenous or exogenous causes of immunosuppression, those who have a genetic propensity to cSCCs, such as XP, and individuals with diffuse actinic damage. Within these groups of high-risk populations, individual patients with high-risk factors should be followed more closely for prompt diagnosis, prompt confirmation by means of biopsy and treatment.

High-risk patients often exhibit field cancerization, which refers to the presence of multiple foci of genetically altered cells in clinically normal-appearing skin; such foci have the capacity to proliferate and invade tissue.¹⁵⁴ This phenomenon is usually seen in chronically immunosuppressed individuals who are fair skinned and have a history of excessive sun exposure over many years. These patients often have hundreds of lesions, including warts, AKs, in situ, and invasive cSCCs, and may develop multiple tumor recurrences despite adequate therapy.

Cutaneous squamous cell carcinomas at high risk for recurrence are identified first and treated by MMS. Because these patients often have numerous lesions, disc excision with second intention healing or destructive therapies such as ED&C, cryotherapy, stronger topical acids, or ablative laser vaporization are often preferred for low-risk lesions because they can be used to treat multiple tumors in a single visit. After all the invasive cSCCs have been treated, field treatment is performed on the remaining in situ disease with topical modalities, such as imiquimod, 5-FU or ingenol mebutate, PDT, or other superficially ablative techniques. Low-dose retinoids may be considered if patients continue to develop multiple new lesions. Retinoids will slow tumor growth, but have no effect on the course of existing lesions.

Treatment of the Challenging Patient

The patient’s medical, mental, and functional status should be considered when choosing a treatment modality. Since most skin cancers are treated with local anesthesia, medical contraindications to the surgical treatment of most cSCCs are rare. The relative risks and benefits of surgery need to be weighed in patients who are not mentally competent to give

informed consent or for those who are not able to cooperate with the procedure. In such cases, the patient’s guardian is involved in the discussion and if the decision is made to proceed with surgery, it may be performed under a higher level of sedation or general anesthesia.

The age of the patient should not affect the decision to proceed or not to proceed with surgery. However, the patient’s overall level of function, health, mental state, life expectancy, and willingness to undergo the proposed procedure should be weighed against the aggressiveness of the tumor and the likelihood that the tumor will affect the patient’s quality of life or life expectancy. For example, a small low-risk cSCC in a patient with advanced Alzheimer disease may not warrant aggressive treatment, whereas a rapidly growing cSCC should be surgically removed.

For patients who are deemed poor risks for surgery, radiotherapy is a reasonable alternative for many cSCCs. However, the need for 15 to 30 visits may be more difficult for the patient and their caregivers than a 30-minute procedure in the dermatologist’s office. Partial or incomplete treatments such as topical 5-FU for infiltrative NMSC should be avoided as it gives the patient a false sense that the problem has been addressed, whereas the tumor continues to grow under the surface only to require more extensive surgery in the future.

Cost Analysis

In an era of an unrecognized skin cancer epidemic, decreasing reimbursement, insurer policy changes, and increasing pressure to deliver cost-effective care, physicians and insurers should understand the total cost of different skin cancer treatment modalities to determine which yields the best value for patients. Much of the cost analysis in the literature does not differentiate between BCC and cSCC but lumps them into the categories of NMSC or keratinocyte carcinoma.^{155–160} In the following discussion, BCC is specified as it was used as an example in the published literature, but the fees and comparisons made are identical for a cSCC of the same size and location because the same CPT (Current Physician

Terminology) procedure codes are used. Compared with other cancers, the relative magnitude of NMSC treatment costs is currently small because NMSC is usually managed efficiently and effectively, primarily in an office-based setting. In one study, 158 the average cost to Medicare per episode of NMSC when performed in a physician’s office setting was found to be \$492. In contrast, the average cost per episode of care in inpatient and outpatient facility settings was \$5,337 and \$1,043, respectively (Table 5).¹⁵¹

Tumor destruction by office-based surgical procedures, such as ED&C, and cryosurgery are the lowest cost options for the treatment of NMSC. Electrodesiccation and curettage is certainly the least expensive of these treatment modalities for BCC or cSCC. However, there are important limitations and reservations to consider when using destructive techniques to treat tumors including equipment cost, patient discomfort, recurrence rates, and cosmetic outcome.

Tumor destruction by nonsurgical methods includes topical chemotherapy with 5-FU, topical immunotherapy with imiquimod, PDT using topical ALA or MAL, cryotherapy, and radiation therapy. Imiquimod has been touted as a relatively inexpensive, nonsurgical

treatment of NMSC, but it is as expensive as office-based excision and has a higher recurrence rate. Some authors advocate fractionated radiation as first-line therapy in the treatment of NMSC, particularly in those patients in whom health concerns preclude surgical treatment. However, it has been acknowledged that there are very few health conditions that do not allow a patient to undergo office-based surgery with a local anesthetic. There are also other important reservations regarding the use of radiation therapy. A course of radiation treatment is very expensive and requires 15 to 30 treatment visits. Surgical treatments like MMS usually only necessitate 2 visits, 1 for the surgery itself and 1 for suture removal. A Canadian study found the direct cost of treating a patient with a single BCC to be \$871 (range \$630–1,159) using MMS and \$3,625 (range \$3,430–3,971) using radiation therapy.¹⁶¹ These figures for radiation therapy are 267% to 316% more expensive than the cost of MMS. Tumor removal by office-based surgery remains relatively inexpensive when compared with radiation therapy. Standard surgical excision and MMS are among the lowest cost options for the treatment of NMSC.

Several studies have looked at the comparative cost of MMS versus SSE for NMSC. MMS has been found to

TABLE 5. Effect of Surgery Setting on Cost of NMSC Surgery

<i>Date</i>	<i>Study</i>	<i>Authors</i>	<i>Office-Based Surgery</i>	<i>ASC-Based Surgery</i>	<i>Hospital O.R.-Based Surgery</i>
1998	Mohs micrographic surgery: A cost analysis	Cook and Zitelli ¹⁵⁷	\$1,270	\$1,973	N/A
2001	Cost of nonmelanoma skin cancer treatment in the United States	Chen and colleagues ¹⁵⁶	\$492	\$1,043	\$5,337
2004	Mohs micrographic surgery versus traditional surgical excision	Bialy and colleagues ¹⁵⁵	\$970	\$1,399	N/A
2006	Treatment patterns and costs of nonmelanoma skin cancer management	Chen and colleagues ¹⁵⁸	\$500	\$935	\$4,345
2009	An RVU based cost comparison—effect of the loss of the Mohs multiple surgery reduction exemption	Rogers and Coldiron ¹⁵⁹	\$1,131	\$2,334	\$2,680–\$3,085
2012	Cost analysis: Mohs micrographic surgery	Ravitskiy and colleagues ¹⁶⁰	\$1,010	\$2,507.10	N/A
Average cost			\$895.50	\$1,698.52	\$4,188.17

OR, operating room; RVU, relative value unit.

have a similar cost to SSE in the office and is less expensive than surgical excision using intraoperative frozen section margin control. In contrast, a group from the Netherlands found MMS to be more expensive than traditional surgery; however, as MMS is likely to produce extremely high cure rates, it was acknowledged as cost-effective.

There remains a misperception in the medical community that MMS is a very expensive procedure. Mohs micrographic surgery includes preoperative medical evaluation, surgery, pathology, anesthesia, and supply expenses in the payment for the global primary code(s). With MMS, a single payment is made to a single provider. When a patient is treated for skin cancer in an operating room, in addition to the surgical fee, additional fees are billed for use of the operating room, pathology, and frequently an anesthesiologist. Also, frequently overlooked expenses related to the procedure are physician fees for medical clearance for surgery, blood work, x-rays, and electrocardiograms. The unexpected result is that the cost for the excision alone seems lower than for MMS but the additional expenses mentioned above are not taken into account and are difficult for insurers to track.

Rogers and Coldiron¹⁵⁹ compared the Medicare cost of a variety of treatment modalities for a single BCC of the cheek based on 2008 relative value units. The average cost of ED&C was \$471. Topical treatment with imiquimod was \$959 and office-based excision with permanent sections and immediate repair was \$1,006. But, costs varied at various lesions sizes. Excision of a 0.6-cm lesion with immediate repair cost \$807, which was less than the cost of imiquimod. However, as the lesion size increases, excision becomes comparatively more expensive than imiquimod. In their study, the average cost for radiation therapy for a BCC on the cheek was \$2,591 to \$3,460.

Office-based excision with permanent sections, and delay of repair until negative margins are confirmed, increases the cost approximately 16% to \$1,170. Mohs micrographic surgery is somewhat more expensive than office-based SSE with an average cost of \$1,263. This is approximately 25% more expensive than excision with immediate repair and only 8%

more expensive than excision with delayed repair. As the lesion size increases, the cost of MMS becomes much closer to the SSE costs.¹⁵⁹

Standard surgical excision with frozen section margin control in an ASC resulted in average costs of \$2,334. Therefore, ASC cost is 76% to 87% higher than MMS and 132% to 143% higher than office-based excision. If the surgical setting is shifted to a hospital operating room with intravenous sedation, the average cost increased to \$3,085 or 128% to 132% more than MMS and 195% to 207% more than office-based excision.¹⁴⁹

A new type of fee is being charged by many hospital systems, both academic and nonacademic, for office visits and minor surgery. These fees are called “facility fees” which are added to the cost of procedures in the hospital setting. Thus, in studies that show an increase in cost of treatment of NMSC, an unexpected and disproportionate increase is seen in hospital-based charges.¹⁶² Although hospital facility fees specifically have not been studied with respect to NMSC, when such fees are charged, our experience is that the charge is comparable or even more than with an ASC.

As health care costs explode and insurers attempt to contain costs and decrease health care use, it is important to realize that office-based procedures, such as ED&C, SSE, and MMS are the most affordable options. Physician-office settings provide the lowest cost per episode of care (\$492 per episode) and are the dominant setting for NMSC care. Dermatologists manage the most NMSC episodes and use a wider range of treatment options than other specialists. Legislative or regulatory measures that attempt to decrease costs by restricting or limiting the use of office-based surgery will paradoxically only result in increasing overall costs.

Conclusion

NMSC has reached epidemic proportions in the United States with more than 3.5 million new cases treated each year, including more than 700,000 cSCC. Cutaneous squamous cell carcinoma can invade surrounding tissue, causing local destruction and

disfigurement; aggressive high-risk lesions have a great potential to recur and metastasize. Because the risk of metastasis and death from cSCC dramatically increases for tumors recurring after treatment, the best chance of a cure is with the most effective primary therapy. There are multiple modalities to treat cSCC, but cure rates, adverse effects, cosmesis, and cost varies. Nonsurgical modalities are used to treat AKs, field cancerization, and low-risk cSCCis-BD. Surgical modalities typically provide the optimal results for cSCC, and MMS affords the highest cure rate, maximal tissue preservation, and the best cosmetic outcome. Mohs micrographic surgery is an effective modality for all cSCCs and remains the preferred treatment of high-risk tumors. When performed in the office setting with immediate reconstruction, it is an efficient and cost-effective procedure.

References

1. Rogers HW, Weinstock MA, Harris AR, Hinckley MR, et al. Incidence estimate of nonmelanoma skin cancer in the United States, 2006. *Arch Dermatol* 2010;146:283–7.
2. Rigel DS, Friedman RJ, Kopf AW. Lifetime risk for development of skin cancer in the U.S. population: current estimate is now 1 in 5. *J Am Acad Dermatol* 1996;35:1012–3.
3. Johnson TM, Rowe DE, Nelson BR, Swanson NA. Squamous cell carcinoma of the skin (excluding lip and oral mucosa). *J Am Acad Dermatol* 1992;26(3 Pt 2):467–84.
4. American Cancer Society. *Cancer facts & figures 2011*. Atlanta: American Cancer Society; 2011.
5. Fears TR, Scotto J. Estimating increases in skin cancer morbidity due to increases in ultraviolet radiation exposure. *Cancer Invest* 1983;1: 119–26.
6. Xiang F, Lucas R, Hales S, Neale R. Incidence of nonmelanoma skin cancer in relation to ambient UV radiation in white populations, 1978–2012: empirical relationships. *JAMA Dermatol* 2014;150:1063–71.
7. Kricger A, Armstrong BK, English DR. Sun exposure and non-melanocytic skin cancer. *Cancer Causes Control* 1994;5:367–92.
8. Halder RM, Bang KM. Skin cancer in blacks in the United States. *Dermatol Clin* 1988;6:397–405.
9. Harris RB, Griffith K, Moon TE. Trends in the incidence of nonmelanoma skin cancers in southeastern Arizona, 1985–1996. *J Am Acad Dermatol* 2001;45:528–36.
10. Jung GW, Metelitsa AI, Dover DC, Salopek TG. Trends in incidence of nonmelanoma skin cancers in Alberta, Canada, 1988–2007. *Br J Dermatol* 2010;163:146–54.
11. Green A, Battistutta D, Hart V, Leslie D, et al. Skin cancer in a subtropical Australian population: incidence and lack of association with occupation. The Nambour Study Group. *Am J Epidemiol* 1996; 144:1034–40.
12. Beissert S, Loser K. Molecular and cellular mechanisms of photocarcinogenesis. *Photochem Photobiol* 2008;84:29–34.

13. Donaldson MR, Coldiron BM. No end in sight: the skin cancer epidemic continues. *Semin Cutan Med Surg* 2011;30:3–5.
14. Karagas MR, Greenberg ER, Spencer SK, Stukel TA, et al. Increase in incidence rates of basal cell and squamous cell skin cancer in New Hampshire, USA. New Hampshire Skin Cancer Study Group. *Int J Cancer* 1999;81:555–9.
15. Athas WF, Hunt WC, Key CR. Changes in nonmelanoma skin cancer incidence between 1977–1978 and 1998–1999 in North-Central New Mexico. *Cancer Epidemiol Biomarkers Prev* 2003;12:1105–8.
16. Kim RH, Armstrong AW. Nonmelanoma skin cancer. *Dermatol Clin* 2012;30:125–39, ix.
17. Rigel DS. Cutaneous ultraviolet exposure and its relationship to the development of skin cancer. *J Am Acad Dermatol* 2008;58(5 Suppl 2): S129–32.
18. Karia PS, Han J, Schmults CD. Cutaneous squamous cell carcinoma: estimated incidence of disease, nodal metastasis, and deaths from disease in the United States, 2012. *J Am Acad Dermatol* 2013;68:957–66.
19. Schmults CD, Karia PS, Carter JB, Han J, et al. Factors predictive of recurrence and death from cutaneous squamous cell carcinoma: a 10-year, single-institution cohort study. *JAMA Dermatol* 2013; 149:541–7.
20. Rowe DE, Carroll RJ, Day CL Jr. Prognostic factors for local recurrence, metastasis, and survival rates in squamous cell carcinoma of the skin, ear, and lip. Implications for treatment modality selection. *J Am Acad Dermatol* 1992;26:976–90.
21. Brantsch KD, Meisner C, Schönfish B, Trilling B, et al. Analysis of risk factors determining prognosis of cutaneous squamous-cell carcinoma: a prospective study. *Lancet Oncol* 2008;9:713–20.
22. McCall CO, Chen SC. Squamous cell carcinoma of the legs in African Americans. *J Am Acad Dermatol* 2002;47:524–9.
23. Mora RG, Pernicario C. Cancer of the skin in blacks. I. A review of 163 black patients with cutaneous squamous cell carcinoma. *J Am Acad Dermatol* 1981;5:535–43.
24. Weinstock MA. Controversies in the public health approach to keratinocyte carcinomas. *Br J Dermatol* 2006;154(Suppl 1):3–4.
25. Weinstock MA. Nonmelanoma skin cancer mortality in the United States, 1969 through 1988. *Arch Dermatol* 1993;129:1286–90.
26. Weinstock MA. Death from skin cancer among the elderly: epidemiological patterns. *Arch Dermatol* 1997;133:1207–9.
27. Weinstock MA, Bogaars HA, Ashley M, Litle V, et al. Nonmelanoma skin cancer mortality. A population-based study. *Arch Dermatol* 1991;127:1194–7.
28. Lewis KG, Weinstock MA. Nonmelanoma skin cancer mortality (1988–2000): the Rhode Island follow-back study. *Arch Dermatol* 2004;140:837–42.
29. Armstrong BK, Kricger A. The epidemiology of UV induced skin cancer. *J Photochem Photobiol B* 2001;63:8–18.
30. Kripke ML. Ultraviolet radiation and immunology: something new under the sun—presidential address. *Cancer Res* 1994;54:6102–5.
31. Kooy AJ, Prens EP, Van Heukelum A, Vuzevski VD, et al. Interferon-gamma-induced ICAM-1 and CD40 expression, complete lack of HLA-DR and CD80 (B7.1), and inconsistent HLA-ABC expression in basal cell carcinoma: a possible role for interleukin-10? *J Pathol* 1999; 187:351–7.
32. de Gruijl FR, Rebel H. Early events in UV carcinogenesis—DNA damage, target cells and mutant p53 foci. *Photochem Photobiol* 2008; 84:382–7.

33. Stern RS, Liebman EJ, Vákevä L. Oral psoralen and ultraviolet-A light (PUVA) treatment of psoriasis and persistent risk of nonmelanoma skin cancer. PUVA Follow-up Study. *J Natl Cancer Inst* 1998;90:1278–84.
34. Patel RV, Clark LN, Lebwohl M, Weinberg JM. Treatments for psoriasis and the risk of malignancy. *J Am Acad Dermatol* 2009;60:1001–17. Erratum in: *J Am Acad Dermatol*. 2009;61(6):1059.
35. English DR, Armstrong BK, Kricker A, Winter MG, et al. Demographic characteristics, pigmentary and cutaneous risk factors for squamous cell carcinoma of the skin: a case-control study. *Int J Cancer* 1998;76:628–34.
36. Hessel CL, Eide MJ, Johnson CC, Krajenta R, et al. Incidence of nonmelanoma skin cancer in a cohort of patients with vitiligo. *J Am Acad Dermatol* 2009;60:929–33.
37. Perry PK, Silverberg NB. Cutaneous malignancy in albinism. *Cutis* 2001;67:427–30.
38. Dzubow LM, Rigel DS, Robins P. Risk factors for local recurrence of primary cutaneous squamous cell carcinomas. Treatment by microscopically controlled excision. *Arch Dermatol* 1982;118:900–2.
39. Marcil I, Stern RS. Risk of developing a subsequent nonmelanoma skin cancer in patients with a history of nonmelanoma skin cancer: a critical review of the literature and meta-analysis. *Arch Dermatol* 2000;136:1524–30.
40. Karagas MR. Occurrence of cutaneous basal cell and squamous cell malignancies among those with a prior history of skin cancer. The Skin Cancer Prevention Study Group. *J Invest Dermatol* 1994;102:10S–13S.
41. Yu HS, Liao WT, Chai CY. Arsenic carcinogenesis in the skin. *J Biomed Sci* 2006;13:657–66.
42. Everall JD, Dowd PM. Influence of environmental factors excluding UV radiation on the incidence of skin cancer. *Bull Cancer* 1978;65:241–7.
43. Edwards MJ, Hirsch RM, Broadwater JR, Netscher DT, et al. Squamous cell carcinoma arising in previously burned or irradiated skin. *Arch Surg* 1989;124:115–7.
44. Hejna WF. Squamous-cell carcinoma developing in the chronic draining sinuses of osteomyelitis. *Cancer* 1965;18:128–32.
45. Nindl I, Gottschling M, Stockfleth E. Human papillomaviruses and non-melanoma skin cancer: basic virology and clinical manifestations. *Dis Markers* 2007;23:247–59. Review.
46. Arnold AW, Hofbauer GF. Human papillomavirus and squamous cell cancer of the skin—epidermodysplasia verruciformis-associated human papillomavirus revisited. *Curr Probl Dermatol* 2012;43:49–56.
47. Wang J, Aldabagh B, Yu J, Arron ST. Role of human papillomavirus in cutaneous squamous cell carcinoma: a meta-analysis. *J Am Acad Dermatol* 2014;70:621–9.
48. Davis MM, Hanke CW, Zollinger TW, Montebello JF, et al. Skin cancer in patients with chronic radiation dermatitis. *J Am Acad Dermatol* 1989;20:608–16.
49. Martin H, Strong E, Spiro RH. Radiation-induced skin cancer of the head and neck. *Cancer* 1970;25:61–71.
50. Berg D, Otley CC. Skin cancer in organ transplant recipients: epidemiology, pathogenesis, and management. *J Am Acad Dermatol* 2002;47:1–17.
51. Euvrard S, Kanitakis J, Decullier E, Butnaru AC, et al. Subsequent skin cancers in kidney and heart transplant recipients after the first squamous cell carcinoma. *Transplantation* 2006;81:1093–100.
52. Marshall V. Premalignant and malignant skin tumours in immunosuppressed patients. *Transplantation* 1974;17:272–5.
53. Mullen DL, Silverberg SG, Penn I, Hammond WS. Squamous cell carcinoma of the skin and lip in renal homograft recipients. *Cancer* 1976;37:729–34.
54. Penn I. Immunosuppression and skin cancer. *Clin Plast Surg* 1980;7:361–8.
55. Gupta AK, Cardella CJ, Haberman HF. Cutaneous malignant neoplasms in patients with renal transplants. *Arch Dermatol* 1986;122:1288–93.
56. Perez-Reyes N, Farhi DC. Squamous cell carcinoma of head and neck in patients with well-differentiated lymphocytic lymphoma. *Cancer* 1987;59:540–4.
57. Veness MJ, Quinn DI, Ong CS, Keogh AM, et al. Aggressive cutaneous malignancies following cardiothoracic transplantation: the Australian experience. *Cancer* 1999;85:1758–64.
58. Jensen P, Hansen S, Møller B, Leivestad T, et al. Skin cancer in kidney and heart transplant recipients and different long-term immunosuppressive therapy regimens. *J Am Acad Dermatol* 1999;40(2 Pt 1):177–86.
59. Black AP, Bailey A, Jones L, Turner RJ, et al. p53-specific CD8+ T-cell responses in individuals with cutaneous squamous cell carcinoma. *Br J Dermatol* 2005;153:987–91.
60. Kraemer KH, Lee MM, Scotto J. Xeroderma pigmentosum. Cutaneous, ocular, and neurologic abnormalities in 830 published cases. *Arch Dermatol* 1987;123:241–50.
61. Keeler CE. Albinism, xeroderma pigmentosum, and skin cancer. *Natl Cancer Inst Monogr* 1963;10:349–59.
62. Miller SJ. The National Comprehensive Cancer Network (NCCN) guidelines of care for nonmelanoma skin cancers. *Dermatol Surg* 2000;26:289–92.
63. Petter G, Hausteil UF. Rare and newly described histological variants of cutaneous squamous epithelial carcinoma. Classification by histopathology, cytomorphology and malignant potential [in German]. *Hautarzt* 2001;52:288–97.
64. Wade TR, Kopf AW, Ackerman AB. Bowenoid papulosis of the genitalia. *Arch Dermatol* 1979;115:306–8.
65. Kao GF. Carcinoma arising in Bowen's disease. *Arch Dermatol* 1986;122:1124–6.
66. Mora RG, Perniciaro C, Lee B. Cancer of the skin in blacks. III. A review of nineteen black patients with Bowen's disease. *J Am Acad Dermatol* 1984;11(4 Pt 1):557–62.
67. Cassarino DS, Derienzo DP, Barr RJ. Cutaneous squamous cell carcinoma: a comprehensive clinicopathologic classification—part two. *J Cutan Pathol* 2006;33:261–79.
68. Farasat S, Yu SS, Neel VA, Nehal KS, et al. A new American Joint Committee on Cancer staging system for cutaneous squamous cell carcinoma: creation and rationale for inclusion of tumor (T) characteristics. *J Am Acad Dermatol* 2011;64:1051–9.
69. Jambusaria-Pahlajani A, Kanetsky PA, Karia PS, Hwang WT, et al. Evaluation of AJCC tumor staging for cutaneous squamous cell carcinoma and a proposed alternative tumor staging system. *JAMA Dermatol* 2013;149:402–10.
70. Swanson NA. Mohs surgery. Technique, indications, applications, and the future. *Arch Dermatol* 1983;119:761–73.
71. Swanson NA, Johnson TM. Management of basal and squamous cell carcinoma. In: Cummings C, ed. *Otolaryngology: head and neck surgery*. New York: Mosby Yearbook; 1998; pp. 486–501.
72. Thosani MK, Schneck G, Jones EC. Periocular squamous cell carcinoma. *Dermatol Surg* 2008;34:585–99.

73. Salache SJ. Features associated with recurrence of squamous cell carcinoma. In: Miller SJ, Maloney ME, eds. *Cutaneous Oncology, Pathophysiology, diagnosis and management*. Malden: Blackwell Science; 1998; pp. 494–9.
74. Frierson HF Jr, Cooper PH. Prognostic factors in squamous cell carcinoma of the lower lip. *Hum Pathol* 1986;17:346–54.
75. Dinehart SM, Pollack SV. Metastases from squamous cell carcinoma of the skin and lip. An analysis of twenty-seven cases. *J Am Acad Dermatol* 1989;21(2 Pt 1):241–8.
76. Friedman HI, Cooper PH, Wanebo HJ. Prognostic and therapeutic use of microstaging of cutaneous squamous cell carcinoma of the trunk and extremities. *Cancer* 1985;56:1099–105.
77. Fitzpatrick PJ, Harwood AA. Acute epithelioma—an aggressive squamous cell carcinoma of the skin. *Am J Clin Oncol* 1985;8: 468–71.
78. Kyrgidis A, Tzellos TG, Kechagias N, Patrikidou A. Cutaneous squamous cell carcinoma (SCC) of the head and neck: risk factors of overall and recurrence-free survival. *Eur J Cancer* 2010;46:1563–72.
79. Cherpelis BS, Marcusen C, Lang PG. Prognostic factors for metastasis in squamous cell carcinoma of the skin. *Dermatol Surg* 2002;28:268–73.
80. Lang PG. Management of squamous cell carcinomas and lymph node evaluation. In: Wheeland RG, ed. *Cutaneous surgery*. Philadelphia: WB Saunders; 1994; pp. 752–87.
81. Husseinzadeh N, Zaino R, Nahhas WA, Mortel R. The significance of histologic findings in predicting nodal metastases in invasive squamous cell carcinoma of the vulva. *Gynecol Oncol* 1983;16: 105–11.
82. Barnes AE, Crissman JD, Schellhas HF, Azoury RS. Microinvasive carcinoma of the vulva: a clinicopathologic evaluation. *Obstet Gynecol* 1980;56:234–8.
83. Banks ER, Cooper PH. Adenosquamous carcinoma of the skin: a report of 10 cases. *J Cutan Pathol* 1991;18:227–34.
84. Barr RJ. Classification of cutaneous squamous cell carcinoma. *J Cutan Pathol* 1991;18:225–6.
85. Nappi O, Pettinato G, Wick MR. Adenoid (acantholytic) squamous cell carcinoma of the skin. *J Cutan Pathol* 1989;16:114–21.
86. Breuninger H, Schaumburg-Lever G, Holzschuh J, Horny HP. Desmoplastic squamous cell carcinoma of skin and vermilion surface: a highly malignant subtype of skin cancer. *Cancer* 1997;79:915–9.
87. Goepfert H, Dichtel WJ, Medina JE, Lindberg RD, et al. Perineural invasion in squamous cell skin carcinoma of the head and neck. *Am J Surg* 1984;148:542–7.
88. Lawrence N, Cottel WI. Squamous cell carcinoma of skin with perineural invasion. *J Am Acad Dermatol* 1994;31:30–3.
89. Ross AS, Whalen FM, Elenitsas R, Xu X, et al. Diameter of involved nerves predicts outcomes in cutaneous squamous cell carcinoma with perineural invasion: an investigator-blinded retrospective cohort study. *Dermatol Surg* 2009;35:1859–66.
90. Carter JB, Johnson MM, Chua TL, Karia PS, et al. Outcomes of primary cutaneous squamous cell carcinoma with perineural invasion: an 11-year cohort study. *JAMA Dermatol* 2013;149:35–41.
91. Han A, Ratner D. What is the role of adjuvant radiotherapy in the treatment of cutaneous squamous cell carcinoma with perineural invasion? *Cancer* 2007;109:1053–9.
92. McCord MW, Mendenhall WM, Parsons JT, Amdur RJ, et al. Skin cancer of the head and neck with clinical perineural invasion. *Int J Radiat Oncol Biol Phys* 2000;47:89–93.
93. Clayman GL, Lee JJ, Holsinger FC, Zhou X, et al. Mortality risk from squamous cell skin cancer. *J Clin Oncol* 2005;23:759–65.
94. Novick M, Gard DA, Hardy SB, Spira M. Burn scar carcinoma: a review and analysis of 46 cases. *J Trauma* 1977;17:809–17.
95. Fine JD, Johnson LB, Weiner M, Li KP, et al. Epidermolysis bullosa and the risk of life-threatening cancers: the National EB Registry experience, 1986–2006. *J Am Acad Dermatol* 2009;60:203–11. *PREV* 45.
96. Mallipeddi R. Epidermolysis bullosa and cancer. *Clin Exp Dermatol* 2002;27:616–23.
97. Cohen EB, Komorowski RA, Clowry LJ. Cutaneous complications in renal transplant recipients. *Am J Clin Pathol* 1987;88:32–7.
98. Mehrany K, Weenig RH, Pittelkow MR, Roenigk RK, et al. High recurrence rates of squamous cell carcinoma after Mohs' surgery in patients with chronic lymphocytic leukemia. *Dermatol Surg* 2005;31: 38–42. *PREV* 61.
99. Pack GT, Davis J. Radiation cancer of the skin. *Radiology* 1965;84: 436–42.
100. Glass AG, Hoover RN. The emerging epidemic of melanoma and squamous cell skin cancer. *JAMA* 1989;262:2097–100.
101. Chan JY, Chan RC, Chow VL, To VS, et al. Efficacy of fine-needle aspiration in diagnosing cervical nodal metastasis from nasopharyngeal carcinoma after radiotherapy. *Laryngoscope* 2013; 123:134–9.
102. Friedman M, Mafee MF, Pacella BL Jr, Strorigl TL, et al. Rationale for elective neck dissection in 1990. *Laryngoscope* 1990;100:54–9.
103. Ginsberg LE. MR imaging of perineural tumor spread. *Magn Reson Imaging Clin N Am* 2002;10:511–25. vi.
104. Bailet JW, Mark RJ, Abemayor E, Lee SP, et al. Nasopharyngeal carcinoma: treatment results with primary radiation therapy. *Laryngoscope* 1992;102:965–72.
105. Freeman RG, Knox JM, Heaton CL. The treatment of skin cancer. A statistical study of 1,341 skin tumors comparing results obtained with irradiation, surgery, and curettage followed by electrodesiccation. *Cancer* 1964;17:535–8.
106. Honeycutt WM, Jansen GT. Treatment of squamous cell carcinoma of the skin. *Arch Dermatol* 1973;108:670–2.
107. Belkin D, Carucci JA. Mohs surgery for squamous cell carcinoma. *Dermatol Clin* 2011;29:161–74. vii.
108. Ad Hoc Task Force, Connolly SM, Baker DR, Coldiron BM, Fazio MJ, et al. AAD/ACMS/ASDSA/ASMS 2012 appropriate use criteria for Mohs micrographic surgery: a report of the American Academy of Dermatology, American College of Mohs Surgery, American Society for Dermatologic Surgery Association, and the American Society for Mohs Surgery. *J Am Acad Dermatol* 2012;67: 531–50. Connolly SM, Baker DR, Coldiron BM, Fazio MJ, Storrs PA, Vidimos AT, Zalla MJ, Brewer JD, Begolka WS, Berger TG, Bigby M, Bologna JL, Brodland DG, Collins S, Cronin TA Jr, Dahl MV, Grant-Kels JM, Hanke CW, Hruza GJ, James WD, Lober CW, McBurney EL, Norton SA, Roenigk RK, Wheeland RG, Wisco OJ. AAD/ACMS/ASDSA/ASMS 2012 appropriate use criteria for Mohs micrographic surgery: a report of the American Academy of Dermatology, American College of Mohs Surgery, American Society for Dermatologic Surgery Association, and the American Society for Mohs Surgery. *Dermatol Surg*. 2012 Oct;38(10):1582–603. doi: 10.1111/j.1524-4725.2012.02574.x. Epub 2012 Sep 7. PubMed PMID: 22958088.
109. Kimyai-Asadi A, Goldberg LH, Peterson SR, Silapint S, et al. The incidence of major complications from Mohs micrographic surgery performed in office-based and hospital-based settings. *J Am Acad Dermatol* 2005;53:628–34.

110. Cook JL, Perone JB. A prospective evaluation of the incidence of complications associated with Mohs micrographic surgery. *Arch Dermatol* 2003;139:143–52.
111. Tierney EP, Hanke CW. Cost effectiveness of Mohs micrographic surgery: review of the literature. *J Drugs Dermatol* 2009;8:914–22.
112. Brodland DG, Zitelli JA. Surgical margins for excision of primary cutaneous squamous cell carcinoma. *J Am Acad Dermatol* 1992;27 (2 Pt 1):241–8.
113. Cooper J. Radiation therapy in the treatment of skin cancers. In: Rigel D, Dzubow L, Reintgen D, Bystryjn JC, Marks R, eds. *Cancer of the skin*. Philadelphia: Elsevier Saunders; 2005; pp. 593–605.
114. Mendenhall WM, Amdur RJ, Hinerman RW, Cognetta AB, et al. Radiotherapy for cutaneous squamous and basal cell carcinomas of the head and neck. *Laryngoscope* 2009;119:1994–9.
115. Morrison WH, Garden AS, Ang KK. Radiation therapy for non-melanoma skin carcinomas. *Clin Plast Surg* 1997;24:719–29.
116. Hulyalkar R, Rakkhit T, Garcia-Zuazaga J. The role of radiation therapy in the management of skin cancers. *Dermatol Clin* 2011;29:287–96.
117. Neville JA, Welch E, Leffell DJ. Management of nonmelanoma skin cancer in 2007. *Nat Clin Pract Oncol* 2007;4:462–9.
118. Alam M, Nanda S, Mittal B, Kim NA, et al. The use of brachytherapy in the treatment of non-melanoma skin cancer: a review. *J Am Acad Dermatol* 2011;65:377–88.
119. Bhatnagar A, Loper A. The initial experience of electronic brachytherapy for the treatment of non-melanoma skin cancer. *Radiat Oncol* 2010;5:87–94.
120. Garcia-Serra A, Hinerman RW, Mendenhall WM, Amdur RJ. Carcinoma of the skin with perineural invasion. *Head Neck* 2003;25:1027–33.
121. Petit JY, Avril MF, Margulis A, Chassagne D, et al. Evaluation of cosmetic results of a randomized trial comparing surgery and radiotherapy in the treatment of basal cell carcinoma of the face. *Plast Reconstr Surg* 2000;105:2544–51.
122. Reschly MJ, Shenefelt PD. Controversies in skin surgery: electrodesiccation and curettage versus excision for low-risk, small, well-differentiated squamous cell carcinoma. *J Drugs Dermatol* 2010;9:773–6.
123. Kuflik EG, Gage AA. The five-year cure rate achieved by cryosurgery for skin cancer. *J Am Acad Dermatol* 1991;24:1002–4.
124. Zacarian SA. Cryosurgery of cutaneous carcinomas: an 18-year study of 3,022 patients with 4,228 carcinomas. *J Am Acad Dermatol* 1983;9:947–56.
125. Graham GF, Clark LC. Statistical analysis in cryosurgery of skin cancer. *Clin Dermatol* 1990;8:101–7.
126. Salim A, Leman JA, McColl JH, Chapman R, et al. Randomized comparison of photodynamic therapy with topical 5-fluorouracil in Bowen's disease. *Br J Dermatol* 2003;148:539–43.
127. Morton C, Horn M, Leman J, Tack B, et al. Comparison of topical methyl aminolevulinic acid photodynamic therapy with cryotherapy or fluorouracil for treatment of squamous cell carcinoma in situ: results of a multicenter randomized trial. *Arch Dermatol* 2006;142:729–35.
128. Patel GK, Goodwin R, Chawla M, Laidler P, et al. Imiquimod 5% cream monotherapy for cutaneous squamous cell carcinoma in situ (Bowen's disease): a randomized, double-blind, placebo-controlled trial. *J Am Acad Dermatol* 2006;54:1025–32.
129. Mackenzie-Wood A, Kossard S, de Launey J, Wilkinson B, et al. Imiquimod 5% cream in the treatment of Bowen's disease. *J Am Acad Dermatol* 2001;44:462–70.
130. Cozzi SJ, Le TT, Ogbourne SM, James C, et al. Effective treatment of squamous cell carcinomas with ingenol mebutate gel in immunologically intact SKH1 mice. *Arch Dermatol Res* 2013;305:79–83.
131. Lebwohl M, Shumack S, Stein Gold L, Melgaard A, et al. Long-term follow-up study of ingenol mebutate gel for the treatment of actinic keratoses. *JAMA Dermatol* 2013;149:666–70.
132. Braathen LR, Szeimies RM, Basset-Seguín N, Bissonnette R, et al. Guidelines on the use of photodynamic therapy for nonmelanoma skin cancer: an international consensus. International Society for Photodynamic Therapy in Dermatology, 2005. *J Am Acad Dermatol* 2007;56:125–43.
133. Brightman L, Warycha M, Anolik R, Geronemus R. Do lasers or topicals really work for nonmelanoma skin cancers? *Semin Cutan Med Surg* 2011;30:14–25.
134. Calzavara-Pinton PG. Repetitive photodynamic therapy with topical delta-aminolaevulinic acid as an appropriate approach to the routine treatment of superficial non-melanoma skin tumours. *J Photochem Photobiol B* 1995;29:53–7.
135. Willey A, Mehta S, Lee PK. Reduction in the incidence of squamous cell carcinoma in solid organ transplant recipients treated with cyclic photodynamic therapy. *Dermatol Surg* 2010;36:652–8.
136. Chen J, Ruczinski I, Jorgensen TJ, Yenokyan G, et al. Nonmelanoma skin cancer and risk for subsequent malignancy. *J Natl Cancer Inst* 2008;100:1215–22.
137. Galloway TJ, Morris CG, Mancuso AA, Amdur RJ, et al. Impact of radiographic findings on prognosis for skin carcinoma with clinical perineural invasion. *Cancer* 2005;103:1254–7. *PREV* 92.
138. Jambusaria-Pahlajani A, Hess SD, Katz KA, Berg D, et al. Uncertainty in the perioperative management of high-risk cutaneous squamous cell carcinoma among Mohs surgeons. *Arch Dermatol* 2010;146:1225–31.
139. Mullen JT, Feng L, Xing Y, Mansfield PF, et al. Invasive squamous cell carcinoma of the skin: defining a high-risk group. *Ann Surg Oncol* 2006;13:902–9.
140. Weinberg AS, Ogle CA, Shim EK. Metastatic cutaneous squamous cell carcinoma: an update. *Dermatol Surg* 2007;33:885–99.
141. Veness MJ, Palme CE, Smith M, Cakir B, et al. Cutaneous head and neck squamous cell carcinoma metastatic to cervical lymph nodes (nonparotid): a better outcome with surgery and adjuvant radiotherapy. *Laryngoscope* 2003;113:1827–33.
142. Veness MJ, Morgan GJ, Palme CE, GebSKI V. Surgery and adjuvant radiotherapy in patients with cutaneous head and neck squamous cell carcinoma metastatic to lymph nodes: combined treatment should be considered best practice. *Laryngoscope* 2005;115:870–5.
143. Wang JT, Palme CE, Morgan GJ, GebSKI V, et al. Predictors of outcome in patients with metastatic cutaneous head and neck squamous cell carcinoma involving cervical lymph nodes: improved survival with the addition of adjuvant radiotherapy. *Head Neck* 2012;34:1524–8.
144. Goh A, Howle J, Hughes M, Veness MJ. Managing patients with cutaneous squamous cell carcinoma metastatic to the axilla or groin lymph nodes. *Australas J Dermatol* 2010;51:113–7.
145. Veness MJ. The important role of radiotherapy in patients with non-melanoma skin cancer and other cutaneous entities. *J Med Imaging Radiat Oncol* 2008;52:278–86.
146. Bernier J, Cooper JS, Pajak TF, van Glabbeke M, et al. Defining risk levels in locally advanced head and neck cancers: a comparative analysis of concurrent postoperative radiation plus chemotherapy trials of the EORTC (#22931) and RTOG (# 9501). *Head Neck* 2005;27:843–50.

147. Audet N, Palme CE, Gullane PJ, Gilbert RW, et al. Cutaneous metastatic squamous cell carcinoma to the parotid gland: analysis and outcome. *Head Neck* 2004;26:727–32.
148. Takahashi A, Imafuku S, Nakayama J, Nakaura J, et al. Sentinel node biopsy for high-risk cutaneous squamous cell carcinoma. *Eur J Surg Oncol* 2014;40:1256–62.
149. Laramore GE, Scott CB, al-Sarraf M, Haselow RE, et al. Adjuvant chemotherapy for resectable squamous cell carcinomas of the head and neck: report on Intergroup Study 0034. *Int J Radiat Oncol Biol Phys* 1992;23:705–13.
150. LeBoeuf NR, Schmults CD. Update on the management of high-risk squamous cell carcinoma. *Semin Cutan Med Surg* 2011;30:26–34.
151. Otley CC, Maragh SL. Reduction of immunosuppression for transplant-associated skin cancer: rationale and evidence of efficacy. *Dermatol Surg* 2005;31:163–8.
152. Euvrard S, Morelon E, Rostaing L, Goffin E, et al; The TUMORAPA study group. Sirolimus and secondary Skin-Cancer Prevention in kidney transplantation. *N Engl J Med* 2012;367:329–39.
153. Kaplan AL, Cook JL. Cutaneous squamous cell carcinoma in patients with chronic lymphocytic leukemia. *Skinmed* 2005;4:300–4.
154. Braakhuis BJ, Tabor MP, Kummer JA, Leemans CR, et al. A genetic explanation of Slaughter's concept of field cancerization: evidence and clinical implications. *Cancer Res* 2003;63:1727–30.
155. Bialy TL, Whalen J, Veledar E, Lafreniere D, et al. Mohs micrographic surgery vs traditional surgical excision: a cost comparison analysis. *Arch Dermatol* 2004;140:736–42.
156. Chen JG, Fleischer AB Jr, Smith ED, Kancler C, et al. Cost of nonmelanoma skin cancer treatment in the United States. *Dermatol Surg* 2001;27:1035–8.
157. Cook J, Zitelli JA. Mohs micrographic surgery: a cost analysis. *J Am Acad Dermatol* 1998;39(5 Pt 1):698–7.
158. Chen JG, Yelverton CB, Polisetty SS, Housman TS, et al. Treatment patterns and cost of nonmelanoma skin cancer management. *Dermatol Surg* 2006;32:1266–71.
159. Rogers HW, Coldiron BM. A relative value unit-based cost comparison of treatment modalities for nonmelanoma skin cancer: effect of the loss of the Mohs multiple surgery reduction exemption. *J Am Acad Dermatol* 2009;61:96–103.
160. Ravitskiy L, Brodland DG, Zitelli JA. Cost analysis: Mohs micrographic surgery. *Dermatol Surg* 2012;38:585–94.
161. Lear W, Mittmann N, Barnes E, Breen D, et al. Cost comparisons of managing complex facial basal cell carcinoma: Canadian study. *J Cutan Med Surg* 2008;12:82–7.
162. Guy GP, Machlin SR, Ekwueme DU, Yabroff KR. Prevalence and costs of skin cancer treatment in the U.S., 2002-2006 and 2007-2011. *Am J Prev Med* 2014;48:183–7.

Address correspondence and reprint requests to: Arielle N. B. Kauvar, MD, New York Laser & Skin Care, 1044 Fifth Avenue, New York, NY 10028, or e-mail: info@nylaseriskincare.com